



The Newborn Clinical Examination Handbook

mychild.ie

Contents

1. Introduction	5	5. Growth monitoring	49
2. The newborn clinical examination	7	6. Infant mental health	51
3. Getting started	9	7. Health promotion	51
• 3.1 Practical tips	7	8. Summary points	53
• 3.2 Setting the scene	8	• Appendix 1 Neonatal jaundice on postnatal ward	55
• 3.3 Short targeted history	8	• Appendix 2 Management of a baby with jaundice in the community	56
• 3.4 Variants of normal	11	• Appendix 3 Management of tongue tie in early infancy	57
4. Head to toe examination	13	• Appendix 4 Anorectal malformations	58
• 4.1 Observing the appearance of the skin	13	• Appendix 5 Brachial plexus injury (Erb's Palsy)	59
• 4.2 Examination of the cranium	17	• Appendix 6 Infant examination by public health nurse within 72 hours of discharge	60
• 4.3 Examination of the face	19	• Appendix 7 Infant examination at six weeks	61
• 4.4 Examination of the nose	20	• Appendix 8 Recommendations 6.1 from DDH Subgroup	62
• 4.5 Examination of the eyes	21	• Appendix 9 Professional Bodies consulted with	63
Screening Pathway 1: Screening for congenital cataract	22	Glossary	64
• 4.6 Examination of the mouth	23	Bibliography	67
• 4.7 Examination of the ears	25	Acknowledgments	68
• 4.8 Examination of the neck	26	Additional Information for Parents	
• 4.9 Examination of the cardiovascular system	27	• www.mychild.ie	
Screening Pathway 2: Screening pathway for newborn CHD using pulse oximetry testing	29	• www.breastfeeding.ie	
• 4.10 Examination of the respiratory system	31	Learning supports:	
• 4.11 Examination of the abdomen	32	• HSE Online e-learning modules:	
• 4.12 Examination of the anus	33	http://www.hse.ie	
Algorithm for examination for anorectal malformations	34	• National Clinical Programme RCPI resources:	
• 4.13 Examination of the genitalia	35	http://www.hse.ie/eng/about/Who/clinical/natclin-prog/paediatricsandneonatology/resources/	
Screening Pathway 3(a): Undescended testes in the newborn	37		
Screening pathway 3(b): Undescended testes at six weeks	38		
• 4.14 Examination of the spine	39		
• 4.15 Examination of the upper limbs	40		
• 4.16 Examination of the lower limbs	41		
• 4.17 Examination of the hips	42		
Screening Pathway 4(a): DDH Screening in the newborn	43		
Screening Pathway 4(b): DDH Screening at 6 weeks	44		
• 4.18 Examination of the central nervous system	45		
• 4.19 Examination for normal newborn reflexes	46		

Foreword

'The early years last a lifetime.'

We have the youngest population in the EU, with children under the age of 18 accounting for 25% of our citizens. Our birth rate, while decreasing, is high by comparison with our EU neighbours. Our population has grown and become more diverse. In the last two decades, in particular, the changes in family structures reflect wider societal changes in Ireland. There is increased public expectation of patient and service user experiences. The health service is required to navigate and plan for the challenges that this presents. One of the ways we can do this is by developing the capacity of frontline staff in order to improve quality, safety and outcomes. With this in mind we have developed the Newborn Clinical Examination Handbook. By using this handbook you will be applying evidence and knowledge gained from research and practice wisdom to deliver better outcomes for the children of Ireland. We know that communities of good practice have greater potential to achieve better outcomes.

Examining the infants in your care using the Newborn Clinical Examination methodology means that you are part of the delivery of Ireland's child health programme - the National Healthy Childhood Programme. The programme is similar to international models and includes child health screening, vaccinations and child health assessments. The emphasis is on the impact of the early years.

There is an ever-increasing body of evidence highlighting the effectiveness of early intervention to positively impact the health and wellbeing of our children and to prevent adverse outcomes. The importance of infant mental health and early attachment on a child's social and emotional wellbeing is now widely accepted. This means that, as healthcare professionals, we have a key role in supporting parents throughout the transition to parenthood, helping them to lay the foundations for a lifetime of health within their families.

By using the step by step methods outlined in this handbook you are creating the potential for that vital early intervention. The Newborn Clinical Examination is carried out at 3 distinct time points-within 72 hours of birth by a doctor or specialist midwife; within 72 hours of discharge by the public health nurse and at 6 weeks by the GP. While there is focus on screening for conditions of the eyes, heart, hips and testes and the most significant red flag issues, this handbook is also packed with practical tips that will enhance your ability to continuously develop your own practice.

The handbook was developed by the Newborn Clinical Examination Subgroup of the National Steering Group for the Revised Child Health Programme. It is the result of extensive review by and consultation with experts of all disciplines in the area of the care of the newborn infant.

We hope that this Newborn Clinical Examination Handbook will prove a valuable asset to you in your clinical role and one which you can refer to on an ongoing basis.

We welcome your feedback. You can share your feedback with us at healthy.childhood@hse.ie

Prof John Murphy
Consultant Neonatologist,
Clinical Lead Paediatric &
Neonatology Clinical Programme

Dr. Phil Jennings
Director of Public Health/
National Lead Healthy Childhood Programme

1. Introduction

On average over 63,000 babies are born in Ireland every year. Life expectancy for both men and women has increased significantly since the foundation of the state. This has been as a direct result of decreasing mortality rates, in particular infant mortality rates.¹ Children born in Ireland today can expect to live well into their eighties.

One of the ways of achieving and sustaining these outcomes is the delivery of a universal, evidence-based child health programme.

Ireland's child health programme is similar to international models and covers child health assessments, vaccinations and screening. In Ireland the service is free to all children and covers the years from birth up to fourteen years. The number of contacts, the timing of those contacts and the content or components of a child health contact varies from country to country. During that time span the child will be screened for a number of conditions, will receive the Primary Childhood Immunisations Schedule and the Schools Immunisation Programme and will have their developmental progress assessed.

In 2014 the HSE Health & Wellbeing Division commenced a programme of work to review and update the child health programme – Best Health for Children – which was previously updated in 2005. To date this has resulted in the updating of the evidence base for the child health programme, the development of formal structures to support child health screening and the implementation of the Nurture Infant Health & Wellbeing Programme.

One of the common strands identified across all child health systems reviewed was the evidence for having a process in place for the standardised systematic examination of the newborn baby. This was identified, by the National Steering Group for the Revised Child Health Programme, as a key area for development as part of the overall National Healthy Childhood Programme. The Newborn Clinical Examination Subgroup was established to define the elements of newborn clinical examination at the following child health contact points:

- At birth within the first 72 hours
- At the public health nurse visit within 72 hours of discharge from hospital
- At the GP visit at six weeks old

The Newborn Clinical Examination handbook has been produced following extensive review and consultation. The purpose of this document is to assist clinicians to carry out the newborn clinical examination in a systematic and standardised way at the contact points outlined above.

Throughout the book we make reference to infant mental health. There is emerging evidence in relation to the impact of good infant mental health. Aspects of this evidence have been provided by specialists in the field of infant mental health so the clinician undertaking the newborn clinical examination can apply it in a practical way as part of their interaction.

¹ <http://www.cso.ie/en/releasesandpublications/er/ilt/irishlifetablesno162010-2012/>

2. The newborn clinical examination

Immediately after birth every newborn infant is examined and cared for by the midwife in accordance with the Practice Standards for Midwives 2015. The aim of this examination is to confirm the gender of the infant and to identify serious anomalies that require immediate attention.

The purpose of this document is to assist appropriately trained healthcare professionals to carry out the newborn clinical examination in a systematic and standardised way at the following contact points:



Within 72 hours of birth. It is recommended that a full and detailed examination of all babies is carried out at birth, **within the first 72 hours**. This is normally done by a doctor or by a specialist midwife.



Within 72 hours of discharge from hospital. The public health nurse (PHN) visits the mother and infant within 72 hours of discharge from hospital as part of the National Healthy Childhood Programme (NHCP).



At six weeks. The mother and infant attend the GP when the infant is six weeks old. This visit is covered under the Maternity & Infant Scheme.

The Newborn Clinical Examination is described in this document in four broad components:



Assessment:

The **General Physical Examination**, with specific issues of clinical importance highlighted as *red flags*. The core purpose of the examination is to identify significant, important anomalies that might impact on the health of the child. It also represents an opportunity to assess and reassure parents about minor anomalies or normal variants. It is an important examination and sufficient time must be set aside to undertake it thoroughly.



Being sure to screen for specific conditions as part of the newborn examination:

- Eyes – screening for congenital cataract
- Heart – screening for congenital heart disease using pulse oximetry
- Hips – screening for developmental dysplasia of the hip
- Testes – screening for undescended testes



Checking that

- hearing screening has been carried out or is scheduled. This is usually carried out before the infant is discharged from hospital.
- screening for metabolic conditions through the Newborn Bloodspot Screening Programme (Heel Prick Test) has been carried out. Samples on all babies should be collected by heel-prick after 72 hours and before 120 hours from birth. Increasingly babies are being discharged before 72hrs so many tests are being done in the community by PHNs at the first visit.



Documentation

- The findings of the examination should be discussed with the parents and the possible outcomes and referral process should be clearly explained.
- The findings of the examination should be documented in the infant's clinical notes.
- The findings of the examination, any abnormal findings and the outcomes of all screening assessments should be clearly documented in all discharge correspondence to the GP and the PHN.

Competency:

In summary, the newborn clinical examination should be carried out by an appropriately trained professional, the results of the exam should be documented in detail in the chart and the parents should be informed of the results and any follow up required should be clearly explained. Results should be included in the discharge letter to the GP and Public Health Nurse (PHN).

It is recommended that clinicians complete the following online training programmes

- Growth monitoring
- Breastfeeding
- Child safety
- Nutrition

These programmes are available at HSELand:

<http://www.hseland.ie/dash/Account/Login>

Keep an eye on HSELand for further developments as additional e-learning modules will be added over time.

For up-to-date information on Immunisations please refer to the following link:

<http://www.hse.ie/eng/health/immunisation/>

Please Cite: HSE, The Newborn Clinical Examination Handbook, Version 1, October 2018,
The National Healthy Childhood Programme

3. Getting started

A routine newborn clinical examination usually takes between 10-15 minutes to complete.

Below is a list of equipment that will be needed for the newborn clinical examinations:

Disposable paper "Lasso-o" tape	1 2 3
Stethoscope	1 3
Ophthalmoscope	1 3
Disposable tongue depressor	1 2 3
Pen torch	1 2 3
Swabs (for cleaning around the anus)	1 2 3
Pulse oximeter	1
Measuring tape or standardised measuring mat	1 2 3
Appropriate UK-WHO Growth chart	1 3
Baby's medical records or PHR	1 2 3
Scales (if you will be weighing the baby during this assessment)	1 2 3
NG tube	1
A small mirror	1
Size 6 Fr catheter	1
Disposable gloves if desired by the examiner or the parents	1 2 3



The clinical examination of the infant should ideally be performed in the presence of a parent.

- Examine the infant on a firm flat surface, in a warm room, with good lighting. It is mostly undertaken on an examination table or on the mother's bed. Examining in the newborn cot is less favoured. The excessive bending is uncomfortable for the clinician and there is insufficient space to manipulate the infant and examine the hips properly.
- Observe the hospital's hand washing protocols before and after every examination.
- Observe hospital policy regarding patient identification.
- Ensure copy of the correct UK-WHO growth chart is in the clinical file.

3.1 Practical tips

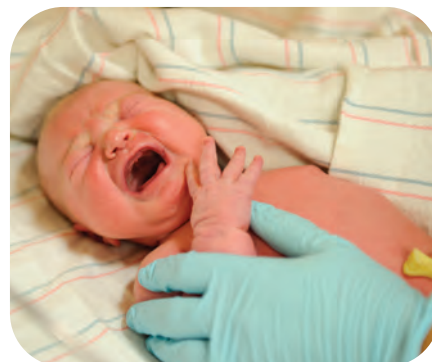Where possible, this assessment should be completed with one parent present. Before you start the examination introduce yourself to the parent and check their baby's identity. Congratulate them on the birth, this may help to put them at ease and establish a rapport. Explain the process of examination to the parent and seek consent. Advise the parent that it is common for babies to cry during this examination. Explain that some parts of the examination may be a little uncomfortable for the infant but that the examination will not cause any pain. Explain to the parent that this is a screening examination, and that not all abnormalities are detected at this examination, particularly in the early newborn period.

"Screening is a process to find out if your baby is at increased risk of a disease or condition. If the test is positive you will be referred for further tests. Screening is never 100% reliable so if you have any worries about your baby please consult your PHN or GP".

3.2 *Setting the scene*

Dignity and Respect

- Explain to the parents what you are doing and seek consent.
- About 85% of babies cry during this exam, reassure the parents that crying is common.
- Listen to and honour parent views and choices regarding planning and delivery of care.
- Respect family values, beliefs and cultural background and consider culturally appropriate supports.
- Respect patient confidentiality.



Information Sharing

- Ask the parents about their concerns for their newborn.
- Explain to the parents that certain conditions may not be evident at birth and that subsequent examinations can also identify issues that require follow up.
- Ensure information is shared in a complete, unbiased and timely manner to ensure parents can effectively participate in care and decision making.
- Arrange for an interpreter if needed.

Participation and Collaboration

- Parents and families are encouraged to participate in care and decision making at the level they choose.
- Wherever possible perform the newborn assessment with at least one parent present.
- Try to include the parent as much as possible throughout the exam.
- This is an opportunity to help facilitate the parent-infant bond by showing the parent their baby's capacities, showing that they are not passive recipients of stimuli – they are complex beings with amazing capacity to communicate. Signs can be very subtle and it will take parents time to learn their newborn's cues.

Adapted from Queensland Clinical Guideline Translating evidence into best practice October 2014

3.3 *Short targeted history*

This should be taken from both the mother and the obstetric case notes or discharge summary. This might include the following:

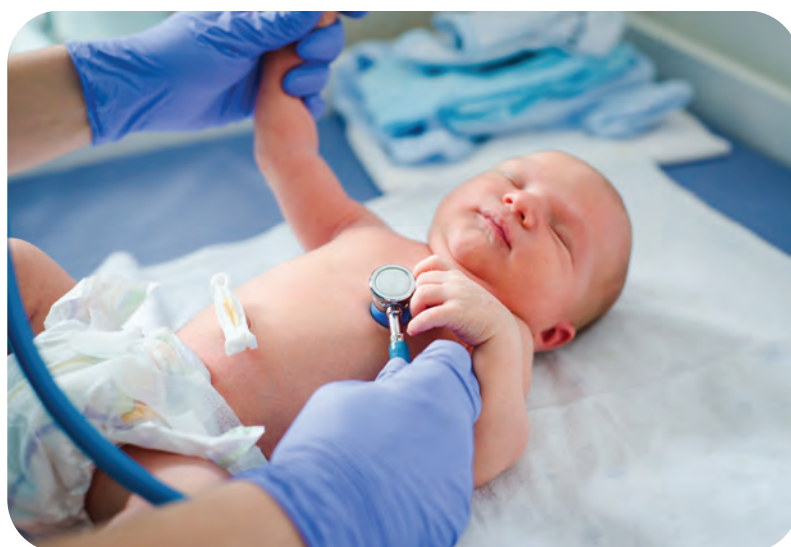- ◆ Labour history including presentation (e.g. cephalic/breech), whether this was a singleton or multiple pregnancy, mode of delivery, whether there was prolonged rupture of the membranes (PROM) for more than 18 hours or maternal fever during the labour (PROM/maternal fever may be indicative of maternal chorioamnionitis).
- ◆ Birth weight and APGAR scores.
- ◆ Any specific issues that were identified during the pregnancy.
- ◆ Whether fetal anomaly scan was performed and what the results were.
- ◆ Any family history of developmental dysplasia of the hip (DDH) in a first degree relative (mother, father, brother or sister).

3.4 Variants of normal*

It is critical to understand normal newborn behaviour to facilitate the recognition of abnormalities.

The following table outlines some of the variables for which there is a range of normality:

Variable	Range of normal values:
Heart rate	100-160 bpm
Respiratory rate	30-60 breaths per minute
Temperature	36.5 – 37.5 °C
Length	48-53 cm
Head circumference	32-38 cm



*Note – these variants of normal apply to term babies born after 37 weeks' gestation.

4. Head to toe examination



The clinical examination begins by noting the **infant's general appearance** - whether they look well or ill. Observe the **infant's state of alertness**. The normal term newborn is alert and responsive.











The infant's **gestational age** can be verified by the following:























Term	Preterm
Term skin is pale/pink and scaling	Preterm skin is red and shiny.
Pinna Recoil - in term infants the pinna readily returns to normal after it is folded over	In preterms the pinna remains deformed
Breast Tissue - term infants, both boys and girls, have palpable breast tissue	Preterms do not have breast tissue.
Plantar Creases - term infants have multiple plantar creases on the soles of their feet.	Preterms do not have plantar creases.






4.1 Observing the appearance of the skin:



Skin colour		Action	Relevant contact points:
Jaundice	 JAUNDICE PATHWAYS (see Appendices 1 & 2)	Follow pathway in Appendices 1 & 2	  
Pallor	This is unusual in the newborn. This could indicate anaemia or a problem with perfusion.	Check capillary refill and consider doing haemoglobin.	 
Cyanosis	Peripheral cyanosis is common in the first 48 hours and usually affects the hands and feet. Central cyanosis needs urgent investigation.	Infants with central cyanosis require admission to SCBU.	
Mottling	Mottling of the skin refers to a red or blue lacy appearance of the baby's skin. This usually disappears once the skin is warmed. Cutis marmorata is a more persistent mottling of the skin that does not disappear when the baby is warmed. Most of the time cutis marmorata is a normal physiologic phenomenon and no formal treatment is necessary. Occasionally it can indicate poor perfusion in infants developing sepsis or can be associated with syndromes.	Check infant's temperature and rewarm where necessary.	  

Skin colour		Action	Relevant contact points:
<p>Milia</p> <p>These are small white spots on the infant's nose, chin or cheeks. These are due to sebaceous glands and resolve in two to three weeks.</p> 	No action required.	  	
<p>Scaling/peeling</p> <p>This is common in term or post-term babies.</p>	No action required.		
<p>Oedema</p> <p>Pitting oedema, if present, is usually abnormal.</p> <p>If non-pitting oedema is present in a female infant, consider Turner's.</p>	<p>If pitting oedema noted, check albumin levels and refer to paediatrics.</p> <p>If Turner's syndrome suspected check chromosomes and refer to paediatrics.</p>	 	




Skin rashes/birthmarks		Action	Relevant contact points:
<p>Salmon patches</p> <p>These are pink, flat, irregular shaped patches on the infant's face or back of the neck. On the face they are commonly found between the eyebrows or on one of the eyelids. At least 70% of infants have one or more salmon patches. The salmon patches on the face fade by one to two years but those on the back of the neck may persist.</p> 	No action required.	  	
<p>Erythema toxicum</p> <p>Seen in 50% of term newborns. It has a 'nettle sting' appearance. There are areas of erythema with white papules. It often begins on the face and spreads to the trunk and limbs but the palms and soles are not affected.</p> 	No action required.	 	
<p>Port wine stains</p> <p>These can be anywhere on the body but most commonly are found on the face, neck, scalp, arms or legs. Port-wine stains are permanent birthmarks that have cosmetic implications. Very rarely these can be a sign of other medical conditions, e.g. If on the face, could indicate intra-cranial problems (Sturge-Weber syndrome).</p> 	Refer to specialist dermatology service.	  	
<p>Bruising</p> <p>May occur after difficult or instrumental deliveries, but spontaneous bruises, petechiae or purpura need investigation.</p>	If spontaneous bruises, petechiae or purpura noted check FBC, PT and APPT.	  	

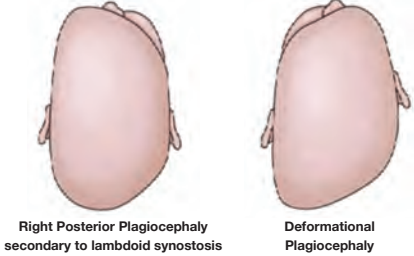






Skin rashes/birthmarks		Action	Relevant contact points:
<p>Mongolian blue spot</p> <p>A 'blue spot' is seen on the buttocks of African (90%) and Asian (80%) infants and less than 10% of fair-haired infants. They are blue-black in colour, and unlike bruises, they are flat with the skin. Also in contrast to bruises they are nontender, and do not change in colour. They fade by two years and disappear by five years. They represent a collection of melanocytes and have no clinical significance.</p> 	<p>No action required.</p>		
<p>Infantile haemangioma</p> <p>Benign vascular neoplasm. Initially blanching or red macule of varying size. The natural history of this lesion is early proliferation and elevation followed by gradual involution over months/years.</p> 	<p>Refer to dermatology if any clinical concerns, e.g. close to the eyes.</p>		
<p>Extensive Haemangiomata</p> <p>Unusual and may be part of a neuro cutaneous syndrome.</p>	<p>Refer to paediatrics.</p>		

4.2 Examination of the head



The head should be examined for size, shape and swellings and the cranial sutures should be palpated. There are normally three cranial sutures - sagittal, coronal, and lambdoid.







Examination of the head		Action	Relevant contact points:
Size	<p>The occipito-frontal circumference (OFC) should be measured at its largest diameter, recorded and plotted on the approved centile charts for Ireland (UKWHO Growth Charts 0-4yrs).</p> <p>In normal infants the head circumference is related to the size of the infant, particularly the body weight.</p> <p>An OFC greater than 38cm should raise the possibility of hydrocephalus.</p> <p>An OFC less than 32cms should raise the possibility of microcephaly.</p> 	<p>If the OFC is greater than 38cm or less than 32cm obtain cranial ultrasound and refer to paediatrics.</p>	
Shape	<p>Moulding is common. In a normal vaginal delivery, the head is moulded into an oblong shape. The sutures are overlapped. It corrects quickly over the first few days after birth.</p> <p>Mild plagiocephaly is common; the confirmatory sign is that the ear on the affected side is more anterior than the ear on the other side.</p>	<p>Educate the parent regarding the importance of tummy time to prevent positional plagiocephaly. "Back to sleep, tummy to play".</p> <p>Consider physiotherapy referral for mild plagiocephaly.</p>	

Examination of the head		Action	Relevant contact points:
<p>Shape</p> <p>Marked asymmetry could suggest craniosynostosis.</p> <p>In sagittal cranial synostosis the sagittal suture is ridged and the infant has an elongated head shape.</p>  <p style="text-align: center;"> <small>Right Posterior Plagiocephaly secondary to lambdoid synostosis</small> <small>Deformational Plagiocephaly</small> </p>	<p>Refer to Consultant Paediatrician if marked asymmetry or cranial synostosis is suspected.</p>		
<p>Fontanelle</p> <p>Palpate the anterior and posterior fontanelles. Ensure the fontanelles are open. Fontanelles should be soft, firm and flat. A large fontanelle and separated sutures may be a variant of normal, but hydrocephalus needs to be excluded by ultrasound.</p>	<p>If hydrocephalus is suspected obtain cranial ultrasound and refer to paediatrics.</p>		
<p>Swellings</p> <p>Caput succedaneum– this very common swelling results from oedema that is not limited by suture lines. This oedema is often pitting, and decreases over time. Most caputs resolve within 48 hours.</p> <p>Cephalhaematoma – a tense swelling usually confined within the suture lines. This does not need treatment but may take several weeks to settle fully.</p> <p>Jaundice may occur as the blood cells are broken down as the swelling resolves.</p>  <p>A sub-galeal haemorrhage is a very rare finding that is suggested by a superficial, boggy swelling without clear margins. A sub-galeal haemorrhage can be lifethreatening leading to acute blood loss.</p>	<p>No action required.</p> <p>No action required.</p> <p>Subgaleal haemorrhage is an emergency. Urgent Consultant Paediatrician review.</p>	  	

4.3 Examination of the face








Perform a general inspection.

Examination of the face		Action	Relevant contact points:
<p>Cleft Lip</p> 	<p>Note if cleft lip is present.</p> 	<p>Refer urgently to the specialist cleft lip and palate service coordinator.</p>	
<p>Dysmorphic features</p>	<p>Note whether dysmorphic features are present on the face.</p>	<p>Refer to Consultant Paediatrician if dysmorphic features present.</p>	 
<p>Chin</p>	<p>Note if micrognathia is present. This is a condition where the jaw is undersized. This normally resolves as the child grows. However it can be a sign of a variety of craniofacial conditions including Pierre-Robin sequence/syndrome which may interfere with the baby's feeding and breathing.</p>	<p>Refer to paediatrics if Pierre-Robin sequence/syndrome suspected.</p>	

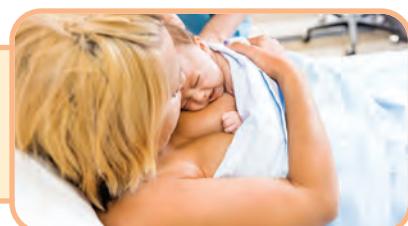4.4 Examination of the nose



Examination of the nose		Action	Relevant contact points:
<p>Shape</p> <p>The newborn baby's nose often appears compressed, particularly if there has been reduced amniotic fluid. This will correct spontaneously in a few days.</p> 	No action required.		
<p>Nasal flaring</p> <p>This is when the nostrils widen as the baby breathes. This is a sign of respiratory distress and needs urgent assessment.</p>	Needs paediatric review.		
<p>Choanal atresia</p>  <p>This should be suspected when there is respiratory difficulty which is relieved by crying, as during crying babies breathe through their mouths rather than their nostrils.</p> <p>In choanal atresia the nasal airway is narrowed or blocked by a bony or membranous septum across the posterior nasopharynx. Most cases (two thirds) are unilateral.</p> <p>Bilateral choanal atresia is an emergency and the infant rapidly becomes cyanosed.</p> <p>The tests for choanal atresia are:</p> <ol style="list-style-type: none"> 1. The lack of movement of a wisp of cotton wool under the nostril. 2. Absence of fogging of a mirror placed under the nostril. 3. Failure to pass a size 6 Fr catheter 3.2 cm down the nostril. 	The baby must be referred to a Paediatric ENT surgeon. Infants with bilateral choanal atresia will need respiratory support (an oral airway).		

PROMOTING POSITIVE INFANT MENTAL HEALTH:

Let the parent know that already their baby can tell the difference between their mother's smell and that of a stranger – and so baby will love to be held close, it will help to soothe baby and build a sense of security.















4.5 Examination of the eyes



The eyes should be examined for placement, shape and symmetry. Observe “visual behaviour”.

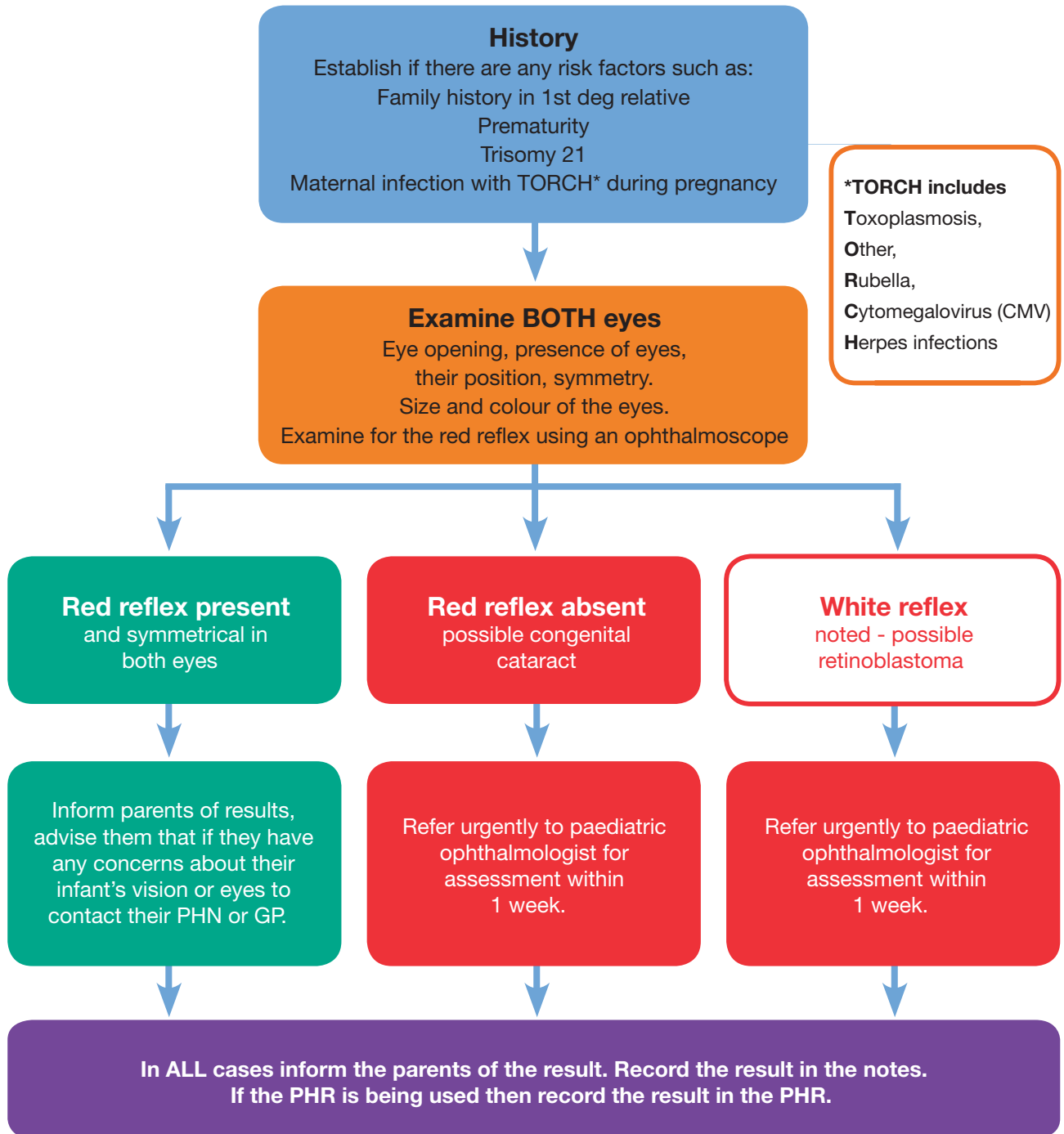
Red Reflex is used to screen for cataract and should be completed. Look for the following:

Examination of the eyes		Action	Relevant contact points:
Ptosis	Ptosis is a significant finding.	Urgent referral to Paediatric Ophthalmologist if the upper eyelid margin is obscuring the pupil. Otherwise advise parents to seek medical attention if it obscures in the future.	 
Large eye	A large eye is indicative of congenital glaucoma (buphthalmos) and is usually associated with corneal oedema.	Urgent referral to Paediatric Ophthalmologist	 
Eye discharge	Discharge originating from the inner canthus and associated with excess watering is due to a blocked nasolacrimal duct	If the discharge is purulent, swabs should be sent for chlamydia and gonorrhoea testing in addition to culture and sensitivity.	  
Conjunctivitis	Mild discharge and/or oedema and redness is common and needs only topical care.		
Subconjunctival haemorrhages	Common in the neonate and do not require any treatment. In older children these can be a sign of nonaccidental injury (NAI), particularly if the haemorrhage was not present at birth.	Follow Children’s First Guidelines if NAI suspected.	  
Red reflex (Congenital cataract)	This should be elicited for both eyes to exclude the presence of a congenital cataract. An absent red reflex is a sign of congenital cataract while a white red reflex could indicate a retinoblastoma. Red reflex is more difficult to see in non-Caucasian children. In dark skinned babies the pupil is more constricted and the retina is pigmented.	See Screening Pathway 1. If there is any difficulty eliciting the red reflex refer to ophthalmology. Absent red reflex is an urgent matter and the infant should be referred to an ophthalmologist and seen within 1 week.	 

PROMOTING POSITIVE INFANT MENTAL HEALTH:

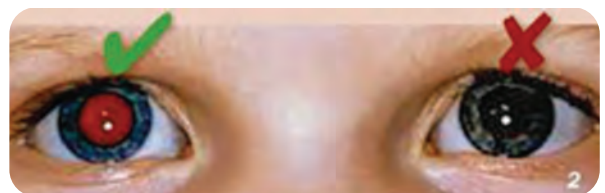Let the parent know that babies can see best from 8 to 12 inches away – a perfect distance for gazing into parents eyes when being held in their arms. Face to face contact is one of their baby’s favourite activities.

**SCREENING PATHWAY 1:
Screening for congenital cataract**











ADDITIONAL POINTS RELEVANT TO 6 WEEK CHECK:




- ◆ Examine eye movements to ensure the baby is 'fixing and following'. Make eye contact with the baby, and move your head from side to side. Does the baby's gaze follow you?
- ◆ If not fixing and following re-examine in 2-3 weeks, may require referral to consultant ophthalmologist.



4.6 Examination of the mouth



Examination of the mouth		Action	Relevant contact points:
<p>Cleft Lip +/- Palate</p> 	<p>Use tongue depressor and light for this examination. Ensure that the gum margin and the hard and soft palate are intact and that the uvula is present.</p> <p>A cleft lip will be obvious.</p> <p>An isolated cleft palate can be missed unless one examines the palate particularly the soft palate.</p> <p>If the uvula is bifid it can be a marker for a submucous cleft. Milk regurgitating through the nostrils is a red flag for a cleft palate.</p> 	<p>If cleft lip/palate is detected refer urgently to the specialist cleft palate service co-ordinator.</p>	
<p>Epstein pearls</p>	<p>White/yellow cystic vesicles on midline of hard palate. Present in 70% of infants. Resolve spontaneously over the first few weeks after birth.</p>	<p>No action required.</p>	
<p>Bohn's nodules</p>	<p>Small white cysts along the dental and buccal parts of the dental ridges. Benign and disappear within 3 months.</p>	<p>No action required.</p>	
<p>Asymmetrical crying facies</p>	<p>Lower lip is pulled down when the infant cries. Usually improves within a month. This should be gone at the 6 week check. This might be associated with other anomalies/syndromes, e.g. di George syndrome.</p>	<p>Review by paediatrics.</p>	
<p>Facial nerve palsy</p>	<p>Facial nerve injury, uni- or bilateral, might manifest by incomplete eyelid closure, asymmetry of the lower face obvious mainly when crying.</p>	<p>May require review by paediatrics.</p>	
<p>Neonatal tooth</p>	<p>These pose a potential risk from inhalation.</p>	<p>Refer to paediatric dentist at National Dental Hospitals. Refer as per local protocols.</p>	





Examination of the mouth		Action	Relevant contact points:
<p>Tongue tie</p> <p>This is where the frenulum is short and the tongue is more adherent to the floor of the mouth.</p> <p>It is only of importance if it significantly interferes with breast feeding.</p> 	<p>See Appendix 3 for more information.</p>		
<p>Masses along mandible</p> <p>Discrete lumps may be felt along the line of the mandible following a forceps delivery.</p> <p>These are areas of fat necrosis and resolve spontaneously.</p>	<p>No action required.</p>		

4.7 Examination of the ears



The ears should be examined for placement, shape and symmetry.

Examine the auditory meatus for patency. Ensure the newborn hearing screening has been performed.

Examination of the ears		Action	Relevant contact points:
Low set ears	Ears are considered to be low-set when the root of the helix (the top of the ear) is on a level below a horizontal line drawn from the corner of the orbit. It is the least specific of clinical signs in the newborn examination. It is a common cause of confusion and unnecessary anxiety.	No action required if isolated finding.	
Pre-auricular skin lesions	Lesions on the face anterior to the ear. They may be fleshy papules (tags) or superficial dimples (pits). Some consist of skin only, others contain some cartilage. They are encountered in 1% of babies. Renal ultrasound examination is not recommended unless there are other anomalies. The lesions are best removed by a plastic surgeon particularly when they contain cartilage.	Refer to plastic surgery for review	
Microtia	Microtia is a disorder where the external ear is underdeveloped. A microtia ear is smaller in size. The right ear is more commonly affected but it can be bilateral. The external auditory canal is absent in most cases. It is encountered in a number of syndromes such as Treacher-Collins. A hearing deficit will be present.	Refer to ENT for review.	
Hemifacial microsomia	The lower half of one side of the face is underdeveloped. It varies in severity but it always includes maldevelopment of the mandible and the ear. The mouth is also involved. It is the second most common defect after cleft lip and palate.	Refer to plastic surgery for review.	

PROMOTING POSITIVE INFANT MENTAL HEALTH:

Tell the parent that their voice is very important to baby – very soon babies can tell their parents' voice from that of a stranger, they can help to soothe their baby by speaking or singing to them gently, and by touching them.



4.8 Examination of the neck




Observe the appearance of the neck, the presence of masses and the range of movement.

Examination of the neck		Action	Relevant contact points:
Size	Very short neck may be indicative of cervical vertebral anomaly such as Klippel-Feil syndrome.	Cervical spine x-ray and refer to paediatrics.	
Shape	Webbed neck can be associated with syndromes e.g. Turner's/Noonan's.	Take bloods for chromosomes and refer to paediatrics.	
Swellings	<p>Sternomastoid tumour - A lump on the lateral side of the neck, at the anterior edge of the sternomastoid. Resolves spontaneously over a few weeks. May be associated with torticollis.</p> <p>Clavicle – these can be injured during birth if shoulder dystocia occurs - fractured clavicle may be felt as crepitus.</p> <p>Branchial cysts - small cysts on the side of the neck that may discharge intermittently. If causing repeated infections or if cosmetically unappealing surgical intervention warranted.</p> <p>Cystic hygroma – soft, transilluminable, fluctuant swelling in the posterior triangle.</p>	<p>If sternomastoid tumour is associated with torticollis refer to physiotherapist.</p> <p>If fractured clavicle is suspected refer for xray and for paediatric review.</p> <p>Refer to Paediatric Surgeon.</p> <p>If cystic hygroma is suspected obtain ultrasound of the neck and refer to ENT.</p>	<p> </p> <p></p> <p> </p> <p></p>
Restricted movement	e.g. torticollis, see above.	Refer to physiotherapy.	

4.9 Examination of the cardiovascular system



Ensure that pulse oximetry has recently been performed on the baby and that the oxygen saturations have been documented. If not, perform this check. The oxygen saturations should be greater than 95% (see Screening Pathway 2).

Examination of the cardiovascular system		Action	Relevant contact points:
Inspection	<p>Tachypnoea can be a sign of cardiac pathology.</p> <p>Examine the mucous membranes. Ensure that the mucous membranes are pink. Make sure that the oxygen saturation has been done.</p>	<p>Refer to paediatrics if tachypnoea present.</p> <p>See Screening Pathway 2 for interpretation of oxygen saturations.</p>	
Palpation	<p>Locate the apex beat which should be in the 4th intercostal space midclavicular line. Look for a left parasternal heave by placing a hand to the left of the sternum. The presence of a left parasternal heave indicates right ventricular hypertrophy and is encountered in cardiac conditions with a left to right shunt.</p> <p>Peripheral pulses - Palpate the presence and volume of the brachial and femoral pulses. The brachial pulses are best felt with forearms extended. Weak brachial pulses may indicate poor cardiac output. Then identify and palpate the femoral pulses. Weak or absent femoral pulses are indicative of coarctation of the aorta.</p>	<p>Refer to paediatrics if left parasternal heave noted.</p> <p>Refer to paediatrics immediately if coarctation of the aorta is suspected as immediate management and cardiac referral is required.</p>	
Auscultation	<p>Auscultate over the precordium.</p>  <p>The normal heart rate is 100-160/min in a newborn. Listen over the 4 valves, pulmonary valve (2nd left interspace) aortic valve (second right interspace), mitral valve (apex), tricuspid valve (lower left sternal edge).</p>	<p>See algorithm on page 30 for the management of cardiac murmurs in neonates.</p>	

Examination of the cardiovascular system		Action	Relevant contact points:
Auscultation (continued)	If a murmur is heard note the position, many murmurs are loudest along the left sternal border. Note if the murmur is soft or harsh. Harsh murmurs are more likely to be clinically significant. When a murmur is auscultated always check the oxygen saturation.	See algoirithm on page 30 for the management of cardiac murmurs in neonates.	

PULSE OXIMETRY SHOULD BE PERFORMED FOR ALL BABIES PRIOR TO DISCHARGE

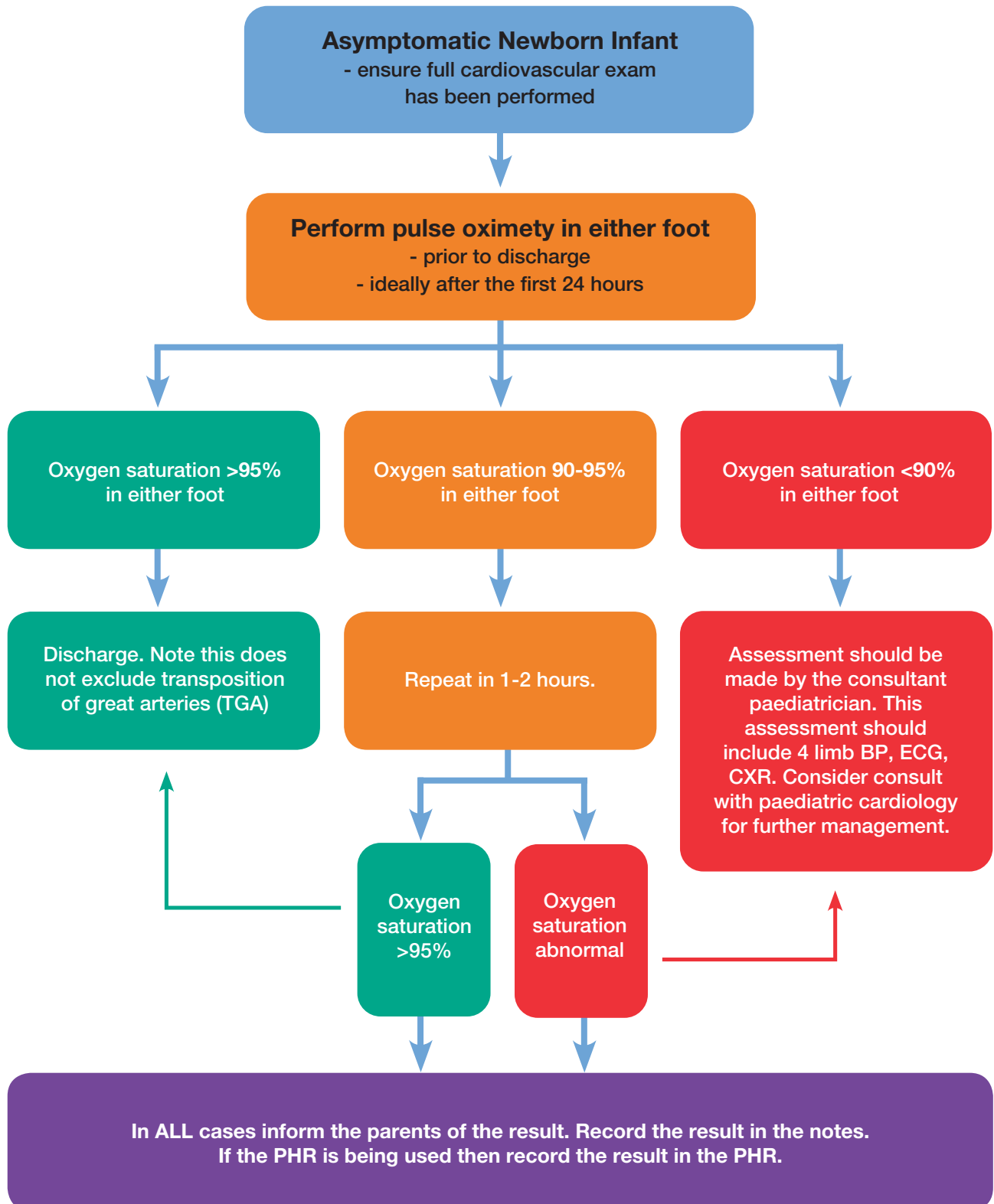
See Screening Pathway 2



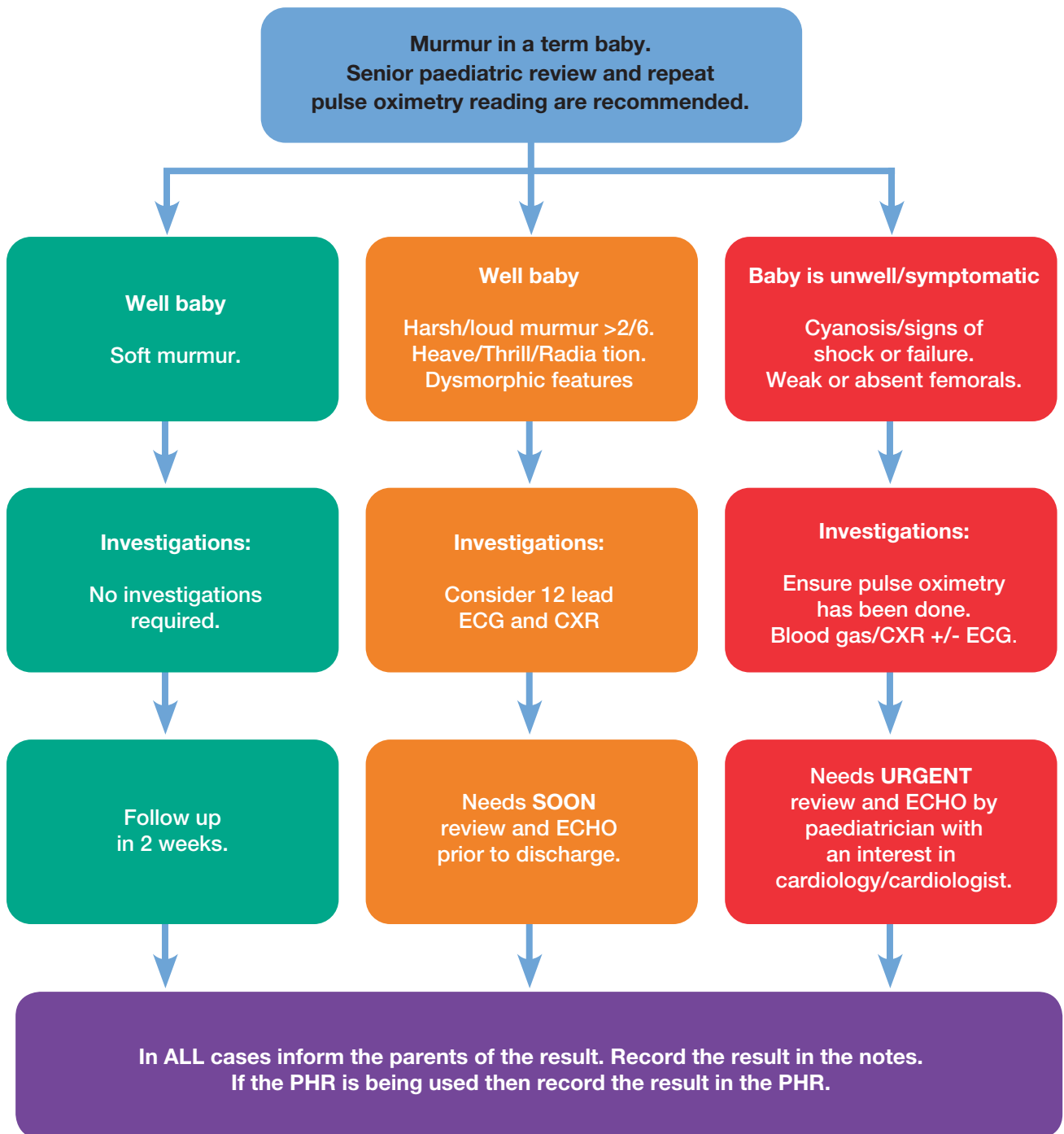SCREENING PATHWAY 2:
Screening pathway for newborn CHD
using pulse oximetry testing.



Adapted from RCPI guideline with thanks




Algorithm for the management for cardiac murmurs in neonates















4.10 Examination of the respiratory system



Examination of the respiratory system		Action	Relevant contact points:
Inspection	<p>Note the rate and pattern of respiration. The normal respiratory rate in a newborn is 30-60 breaths per minute.</p> <p>The presence of a rapid respiratory rate is clinically important and indicates an underlying respiratory problem. The presence of intercostal recession, subcostal recession, flared nostrils, head bobbing, stridor and grunting all point to respiratory distress.</p> <p>Observe chest wall symmetry during respiration. Examine the mucous membranes to ensure that they are pink.</p> <p>Pectus excavatum is a depression seen over the sternum. It is an incidental finding and is not clinically important. Rarely it may be one of the presenting features of Marfan's syndrome.</p> <p>Note the presence of supernumerary nipples.</p>	<p>Refer to paediatrics if rapid respiratory rate is noted or if any signs of respiratory distress or cyanosis are present. If mucous membranes are not pink repeat the pulse oximetry recording and follow Screening Pathway 2.</p> <p>Obtain CXR if the pectus excavatum is severe. Refer to paediatrics if any features of Marfan's are present.</p> <p>No action needed if supernumerary nipples noted.</p>	
Auscultation	<p>Surface anatomy for auscultation: the apices correspond to the upper lobes. The right axilla corresponds to the right middle lobe. The back corresponds to the lower lobe. During auscultation ensure air entry is equal.</p> 	<p>Obtain CXR and refer to paediatrics if air entry is not equal bilaterally.</p>	
Percussion	<p>In general we don't perform percussion on newborns.</p>		




4.11 Examination of the abdomen



Examination of the abdomen		Action	Relevant contact points:
Inspection For distension and for masses. Diastasis recti is normal. The presence of a linea nigra is normal. 	No action required for diastasis recti or linea nigra. See below for management of distension and masses.	 	
Palpation Palpate the liver and spleen for organomegaly. The definition of an enlarged liver is one that is palpable below the right costal margin in the mid-clavicular line. In the newborn a 1-2 cm liver can be normally felt. In infants the spleen enlarges towards the left iliac fossa, unlike in adults where it enlarges across the abdomen. Palpate the abdomen for masses. Approximately 50% of abdominal masses are renal in origin.	Obtain abdominal x-ray and refer to paediatrics if abdominal distension noted or masses/organomegaly detected.	 	
Umbilicus Examine the umbilical stump/clamp to ensure no signs of infection. Check the number of vessels. There should be three vessels, two arteries and one vein. The umbilical cord involutes over the first 7 days and separates at the umbilical stump. Cord separation is defined as being delayed when it is still attached beyond 14 days. A delayed umbilical cord separation, particularly if it becomes infected, can be an indication of an underlying immunodeficiency. Umbilical hernias are common, most resolve spontaneously within a few months.	Refer to paediatrics if any anomalies of the umbilical vessels or cord detected. Observe and refer to Paediatric Surgeon if not resolved by 2 years.	   	
Inguinal hernia These pose a risk of incarceration or strangulation.	Refer to Paediatric Surgeon.	  	

4.12 Examination of the anus

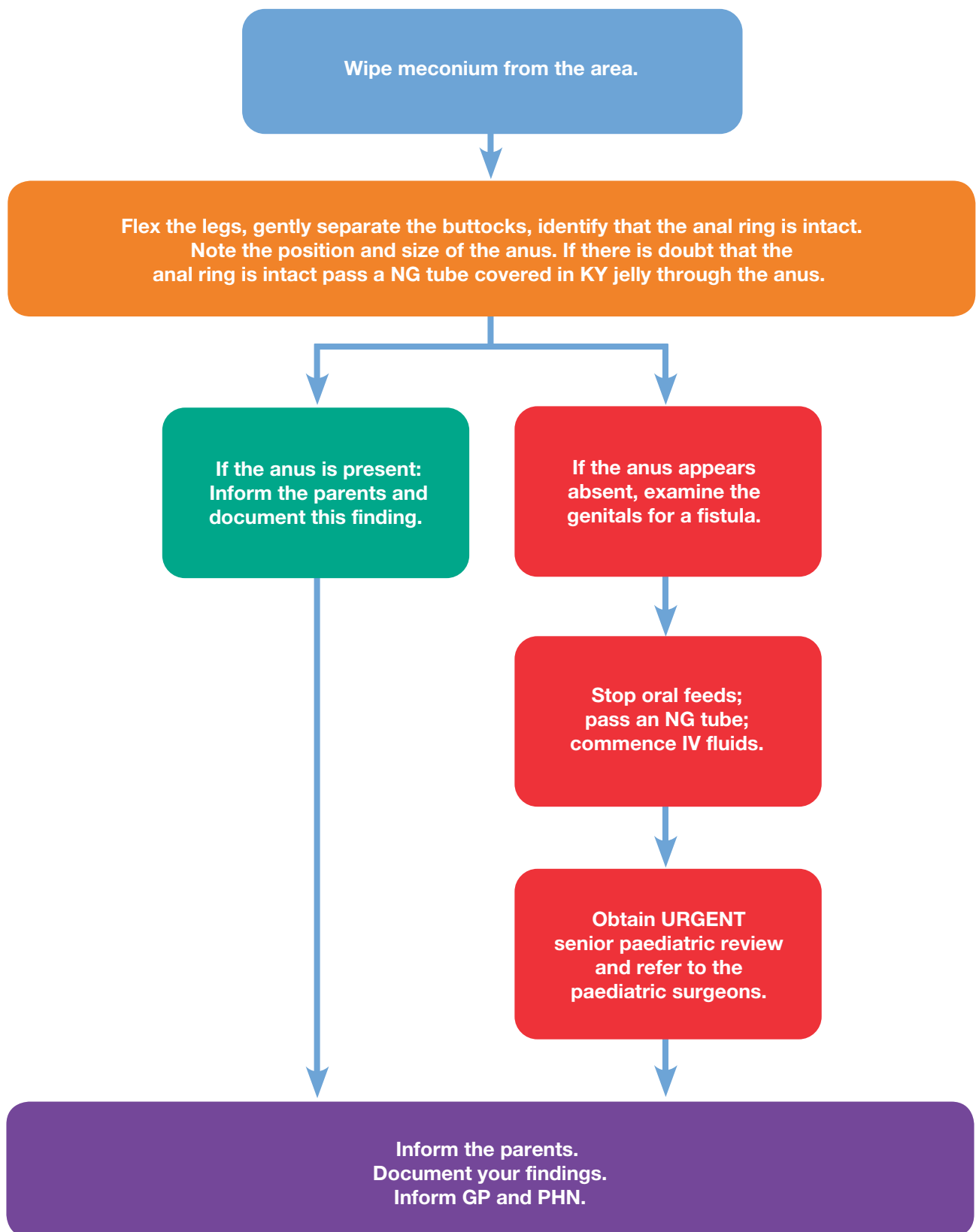


Examination of the anus		Action	Relevant contact points:
<p>Anal Examination</p> 	<p>Separate the buttocks and confirm that the anus is present. Check for position and patency.</p> <p>Anal atresia can easily be overlooked. The presence of meconium on the nappy does not exclude anal atresia because it may have been passed through a perineal, recto-vaginal or a recto-vesical fistula.</p>	<p>The algorithm for anorectal malformation should be followed - see Appendix 4 for more information.</p> <p>If ano-rectal malformation is suspected, the newborn examination should be completed with full consideration of the VACTERL* complexes and of the possibility of dysmorphism.</p>	 

***The acronym VACTERL denotes:**













- ◆ **V:** vertebral anomalies
- ◆ **A:** anorectal anomalies
- ◆ **C:** cardiac anomalies; cleft lip
- ◆ **TE:** tracheo-oesophageal fistula +/- oesophageal atresia
- ◆ **R:** renal anomalies
- ◆ **L:** limb anomalies

**Algorithm for examination
for anorectal malformations:**

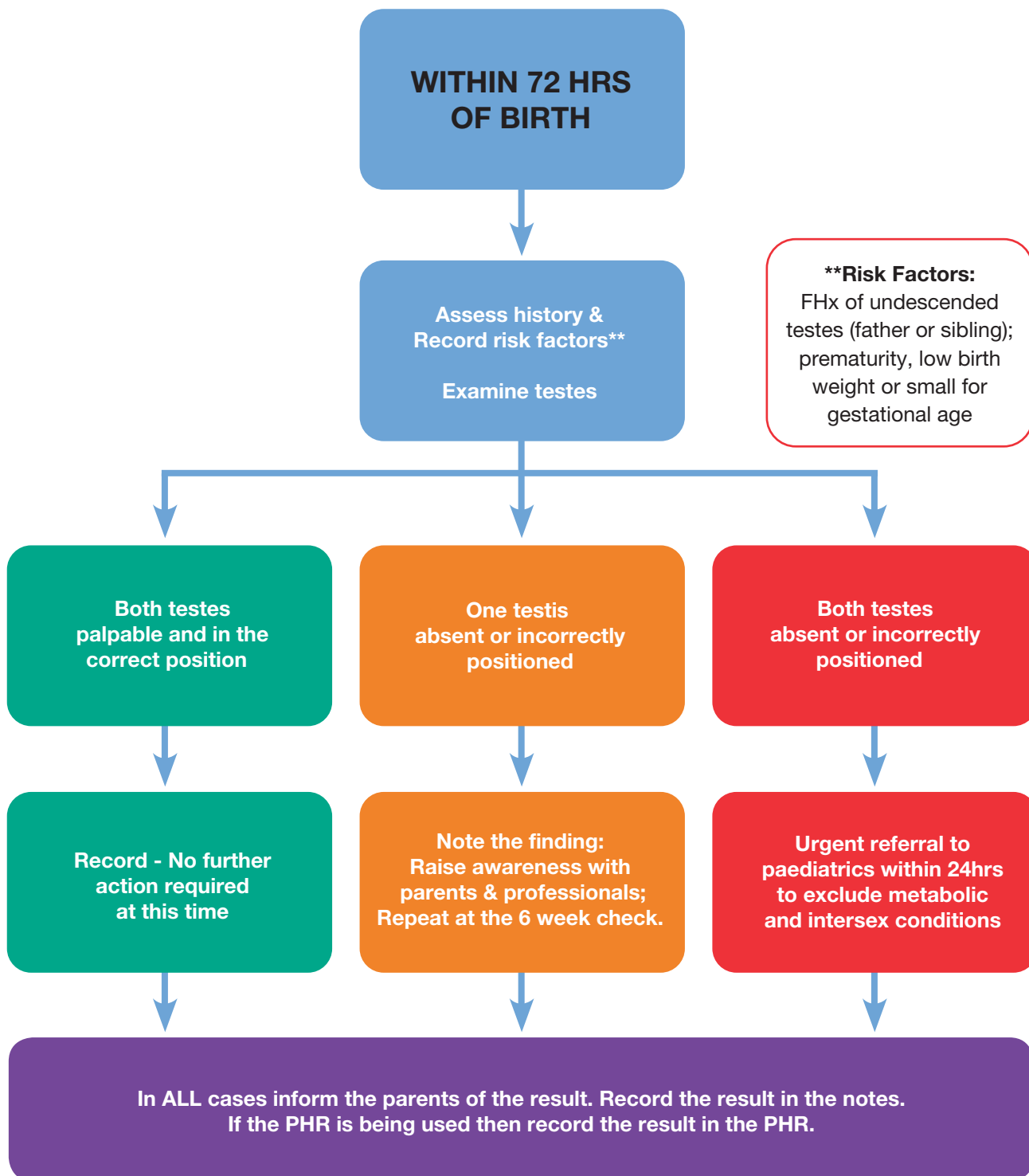


4.13 Examination of the genitalia

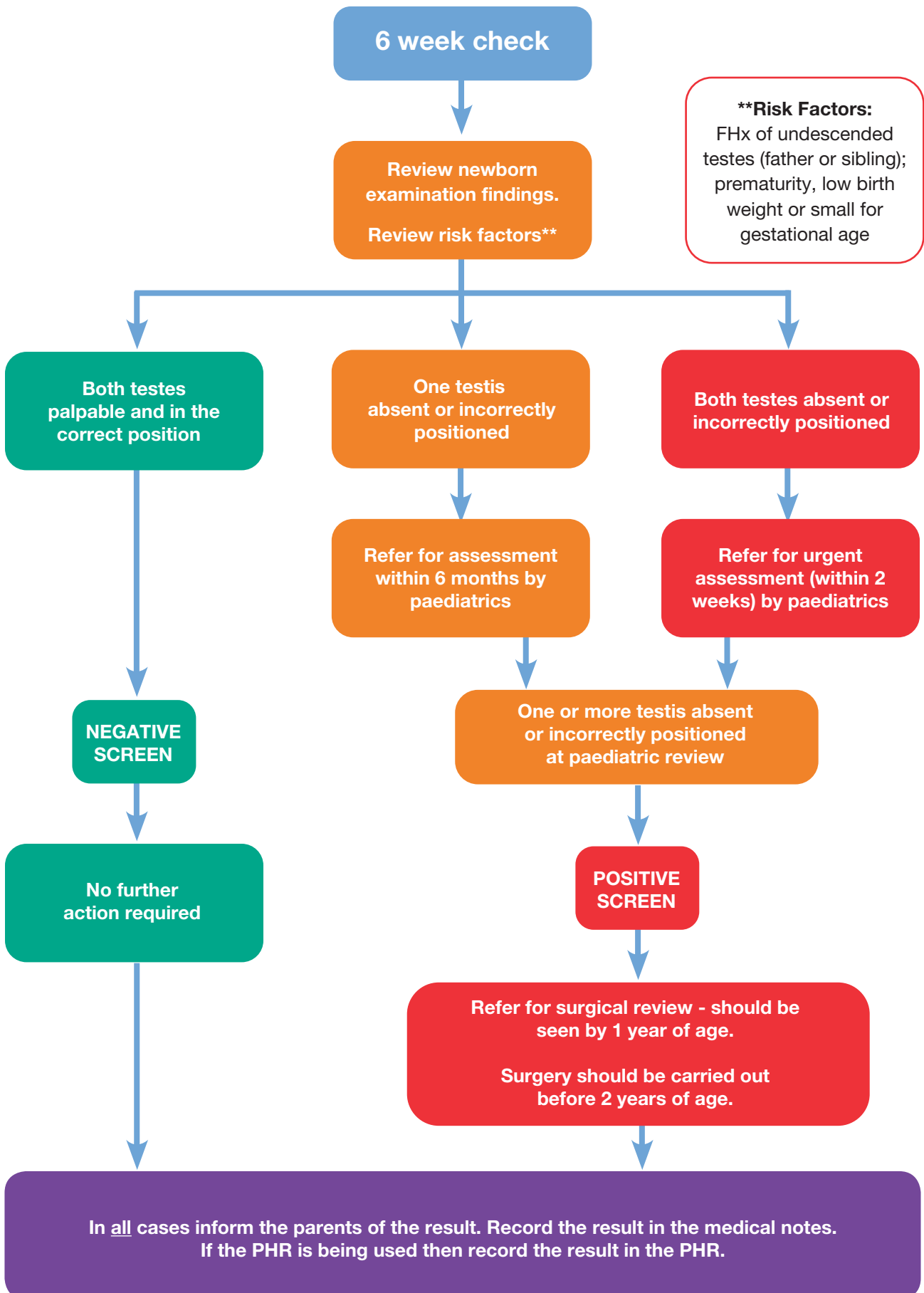


Examination of the genitalia		Action	Relevant contact points:
Ambiguous genitalia	This is an emergency. Junior staff should not inform the parents directly. It is crucial to obtain an early ultrasound to check for the presence of a uterus.	Obtain abdominal/ pelvic ultrasound and the advice of a senior paediatrician.	
Females	<p>Inspect vulva for anatomical anomalies. Note the normal structures, the labia majora and minora.</p> <p>Note if the clitoris is enlarged and hypertrophied. In cases of congenital adrenal hyperplasia (CAH), the enlarged clitoris is commonly associated with a fused labia.</p> <p>A mucous tag is commonly attached to the wall of the vagina and it will resolve spontaneously.</p> <p>Blood-stained vaginal discharge is common (this is similar to a “withdrawal bleed” and is caused by maternal oestrogens).</p>	<p>Refer to paediatrics if CAH suspected.</p> <p>No action required.</p> <p>No action required.</p>	<p>  </p> <p></p> <p> </p> <p> </p>
Males	<p>Check the position of the urethral meatus for hypospadias or epispadias. In a typical case of hypospadias the urethral meatus is on the ventral surface of the glans, the foreskin is hood-shaped, and there is a ventral curvature of the penis called a chordee.</p> <p>Check for scrotal swellings such as hydrocoele. Hydrocoeles are common in the newborn. The testis appears swollen. It may be unilateral or bilateral. One can get above the swelling and it readily transilluminates.</p> <p> Testes – Palpate the scrotum and note whether each testis is present/ palpable in the scrotal sac. If not you may be able to palpate them in the spermatic cord and gently bring them down yourself.</p>	<p>Refer to paediatrics.</p> <p>Refer to paediatrics.</p> <p>As per Screening Pathways 3(a) & 3(b).</p>	<p> </p>

**SCREENING PATHWAY 3(a):
Undescended testes in the newborn**




**SCREENING PATHWAY 3(b):
Undescended testes at 6 weeks**








4.14 Examination of the spine



Examination of the spine		Action	Relevant contact points:
<p>Inspection</p> <p>Inspect for curvature, intact spine and for any midline abnormality.</p> <p>A non-intact spine suggests a neural tube defect such as spina bifida, and is therefore a significant finding.</p>  <p>Tufts of hair, naevi, subcutaneous masses, dimples or other midline abnormalities on an intact spine may suggest spina bifida occulta.</p> <p>The infant's back should always be checked for scoliosis. Two thirds are thoracic, left to right and right to left being equally common.</p>	<p>Refer urgently to paediatrics if a non-intact spine is noted.</p> <p>Refer to paediatrics if other midline abnormalities are detected as a detailed neurological assessment may be necessary.</p> <p>Refer for spinal x-rays to detect vertebral anomalies, if indicated.</p>	<p>1 3</p> <p>1 2 3</p>	
<p>Sacral dimples</p>	<p>Sacral dimples are common. They are not of any significance if they are below the level of the coccyx, in other words between the cleft of the buttocks.</p>	<p>No action required - if below the level of the coccyx.</p>	<p>1 2 3</p>
<p>Palpation</p>	<p>Palpate for spinal abnormalities such as lipomas or dermoid cysts.</p>	<p>Refer to paediatrics to consider a more detailed neurological assessment if palpable spinal abnormalities are noted.</p>	

4.15 Examination of the upper limbs



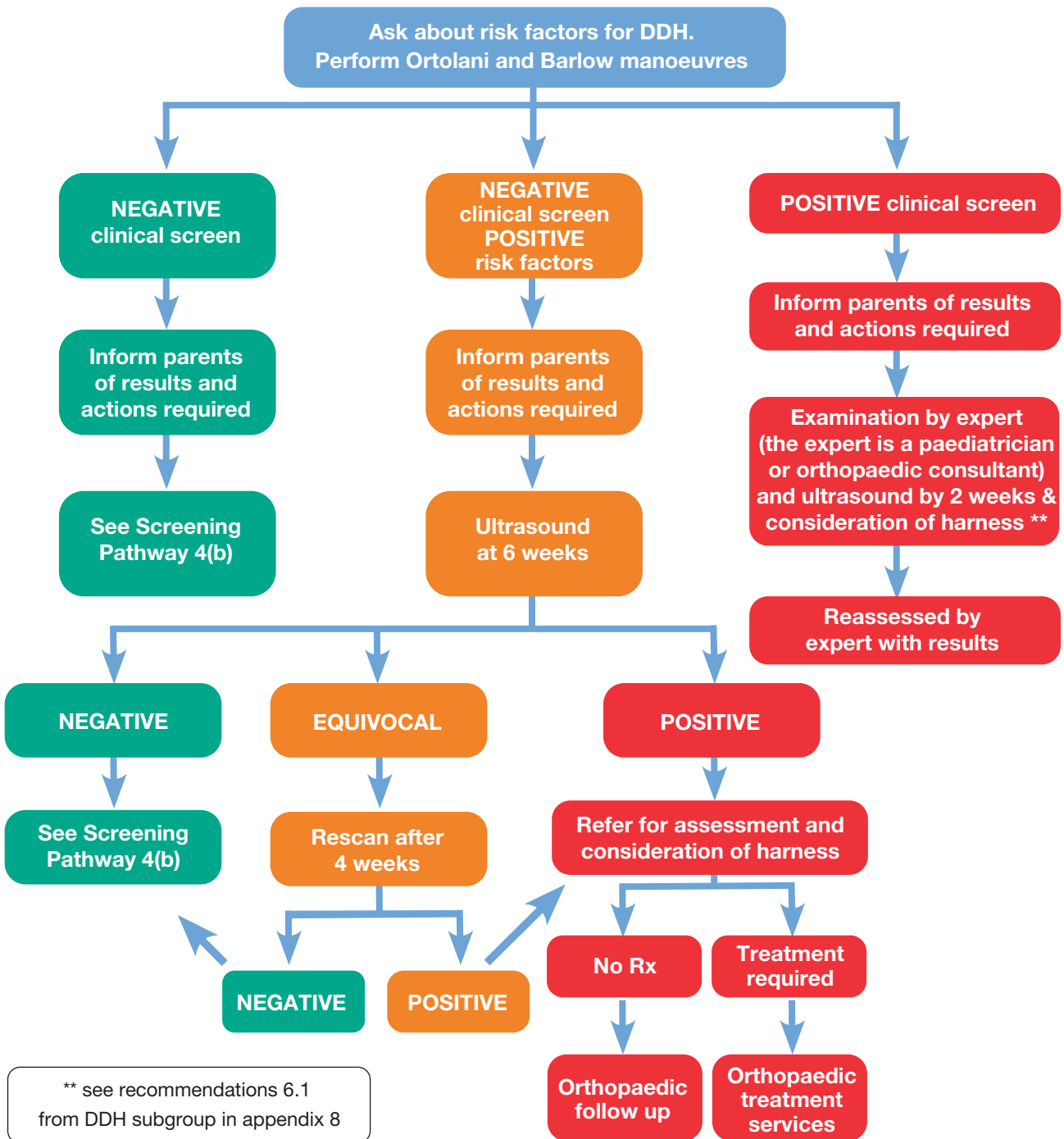
Examination of the upper limbs		Action	Relevant contact points:
<p>Arms</p> 	<p>Examine arms for length, proportion and symmetry.</p> <p>Lack of active movements could suggest a palsy. Palsies such as Erb's Palsy can result from brachial plexus injury and require appropriate management.</p>  <p>Lack of active movements and pain on passive movements of recent onset suggests a fracture or an infection.</p>	<p>See Appendix 5 for more information on Erb's palsy.</p> <p>Refer urgently to paediatrics if acute onset of lack of active movements and/or pain on passive movements.</p>	
<p>Hands</p>	<p>Note the structure and number of digits. Accessory digits or polydactyly:</p> <ul style="list-style-type: none"> • Pre-axial polydactyly is where the extra digit is outside the thumb. This is also known as radial polydactyly. This type of polydactyly is less common.  <ul style="list-style-type: none"> • Post-axial polydactyly is where the extra digit is outside the little finger. This is also called ulnar polydactyly. This finding is more common than pre-axial polydactyly and is particularly common in babies of African descent. <p>Clinodactyly and abnormal palmar crease patterns can be familial but look carefully for other dysmorphic features.</p>	<p>Referral to plastics may be needed. Consider obtaining an x-ray of the hand.</p> <p>Pre-axial polydactyly warrants urgent assessment by a plastic surgeon.</p> <p>No action needed unless other dysmorphic features present.</p>	

4.17 Examination of the hips



Examination of the hips		Action	Relevant contact points:
<p>Developmental dysplasia of the hip (DDH)</p>	<p>Assess for risk factors such as:</p> <ol style="list-style-type: none"> 1. A first degree family history of DDH – a first degree relative is mother, father, brother, sister only. 2. The baby has been a breech presentation after 36 weeks’ gestation, even if cephalic at birth. In multiple births all babies should be screened if any one of the babies is a breech presentation. 	<p>See Screening Pathway 4 for more information.</p> <p>In the Irish DDH targeted ultrasound programme, babies with any risk factors require an ultrasound.</p>	
<p>Examination for DDH</p>	<p>The Ortolani test is one of the tests recommended to screen for DDH. With the infant on their back, flex the knees and grasp the legs with the thumbs along the inner side of the thighs and the middle finger over the greater trochanter. Abduct the leg while the middle finger presses upwards on the greater trochanter. If the hip is dislocated a ‘clunk’ will be felt.</p> <p>The Barlow Test is the other test recommended to screen for DDH. Hold the legs as previously for the Ortolani test. Adduct the hip and apply light downward pressure on the knee. If the hip is unstable, it will pop out of the acetabulum.</p> <p>In other words, when the Ortolani is positive the hip is outside the acetabulum at the start of the test. In the case of the Barlow test, the hip is in the acetabulum at the start of the test.</p>	<p>Practice this examination on the “Hippy mannequin”.</p> <p>See Screening Pathway 4 for more information.</p>	

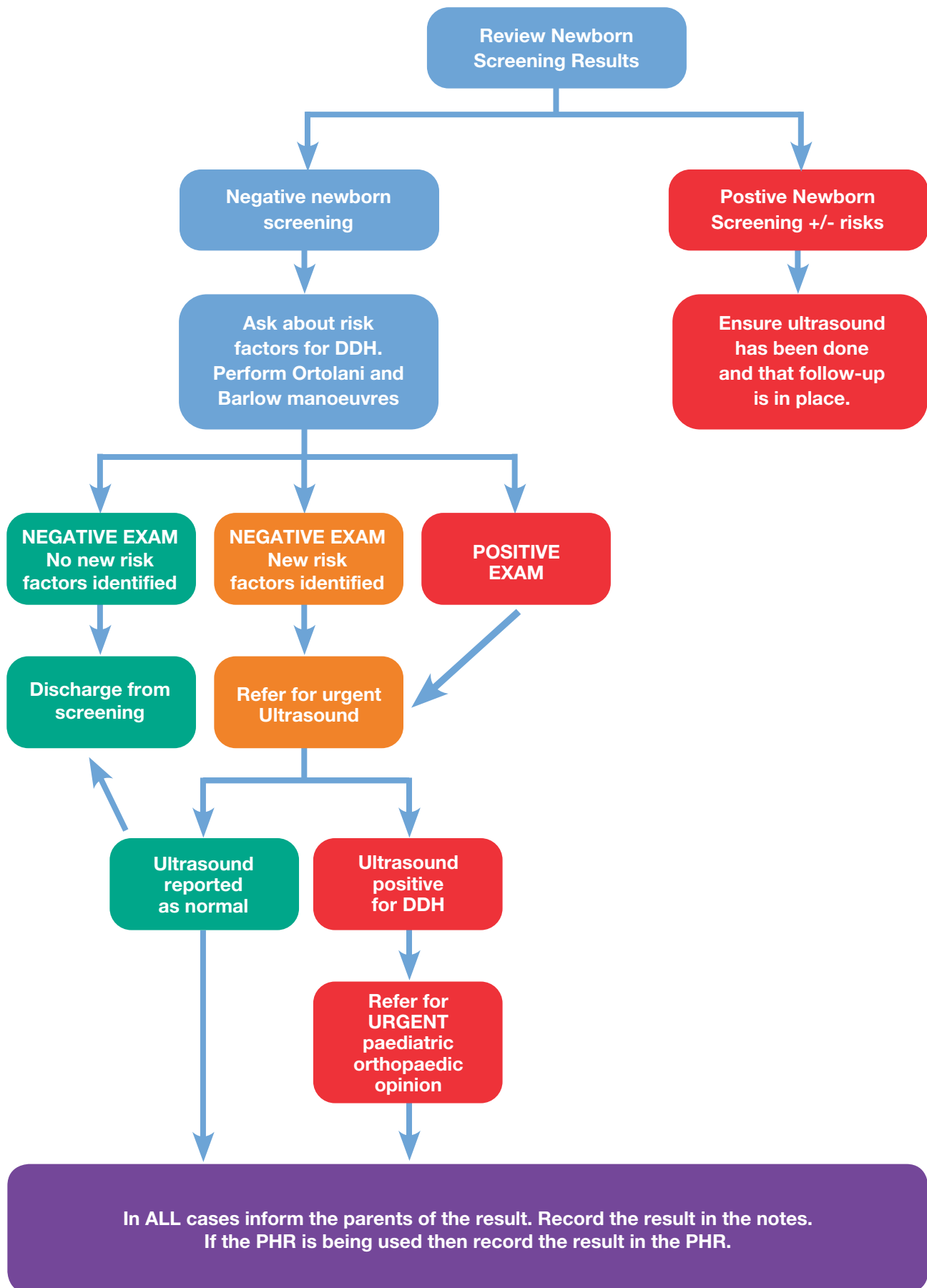**SCREENING PATHWAY 4(a):
DDH Screening in the newborn**



** see recommendations 6.1 from DDH subgroup in appendix 8

**In ALL cases inform the parents of the result. Record the result in the notes.
If the PHR is being used then record the result in the PHR.**

**SCREENING PATHWAY 4(b):
DDH Screening at 6 weeks**



4.18 Examination of the central nervous system

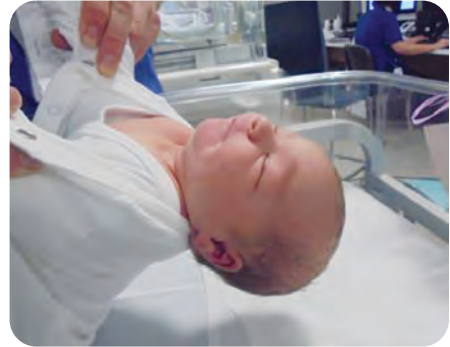

Examination of the central nervous system		Action	Relevant contact points:
General observations	<p>Behavioural status: Always record whether the infant is alert and responsive.</p> <p>Ask if anything unusual in baby's crying.</p> <p>Ask if the infant is able to feed satisfactorily. Note in the chart that the infant is able to feed and eager to feed.</p> <p>Observe baby's posture. The normal newborn lies in a flexed posture because flexor tone predominates.</p> <p>Note presence of spontaneous motor activity.</p>	See table on page 48 for neurological features that require action.	
Muscle tone	<p>Assessment of the infant's tone is important. Tone is defined as the passive resistance to movement about a joint. In the newborn the examination of tone is divided into central and peripheral. The examination of central tone consists of eliciting head lag, ventral suspension and vertical suspension.</p> <p>The examination of peripheral tone involves the assessment of tone in the upper and lower limbs.</p>	See table on page 48 for neurological features that require action.	

Examination of Central Tone

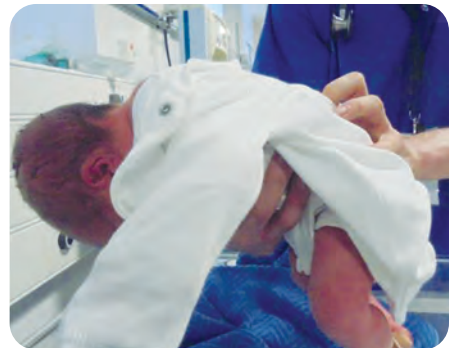For head lag begin by gently holding the infant by the forearms and pulling them upright. There is an initial head lag over the first 30 degrees and then the infant lifts their head and holds it upright momentarily, with rounding of their back.

Normal head lag:



For ventral suspension turn the infant prone and lift them off the couch placing a hand under their chest. The normal newborn lifts both their head and pelvis almost in line with the trunk, with the upper and lower limbs semi-flexed.

Normal ventral suspension:




For vertical suspension hold the infant under the armpits and lift them in an upright position, with the legs dangling. Scissoring or hyperextension of the legs is abnormal and could suggest hypertonia or spasticity.

Examination of of Peripheral Tone

Tone in the upper limbs involves testing the passive range of movement around the shoulders, elbows, wrists and pronation and supination of the forearms. In the lower limbs examine the tone by flexing the hips, then abducting the hips. Next flex and extend the knees and the ankles.

4.19 Examination for normal newborn reflexes



Examination for normal newborn reflexes		Action	Relevant contact points:
Sucking and swallowing	Sucking and swallowing reflexes are present in all term infants and preterm infants over 35 week's gestation.	See table (p48) for neurological features that require action.	
Rooting reflex	When the corner of the infant's mouth is touched, the lower lip on that side and the tongue moves towards the point of stimulation.	See table (p48) for neurological features that require action.	
Grasp reflex	When the infant's palm is stimulated, the hand closes. It disappears by 2-3 months. 	See table (p48) for neurological features that require action.	
The Moro reflex	Explain to the parents that their baby may cry during this assessment. Lift the infant placing one hand behind their head and then other hand behind their back. Allow the head to drop a few degrees. There is a rapid abduction and extension of the arms with opening of the hands. The arms then come together. The Moro reflex is a very useful clinical test when assessing an infant for Erb's Palsy, where the asymmetry is readily obvious. It disappears by 3-4 months. For more information see Appendix 5.	See Appendix 5 for more information on the Moro reflex.	
The Asymmetrical Tonic Neck Reflex	When the infant turns their head to one side, the arm extends to the same side and the contralateral arm flexes. It disappears by 2-3 months of age.	See table (p48) for neurological features that require action.	
The Placing and walking reflexes	The placing reflex is elicited by bringing the anterior aspect of the tibia against the edge of the table. The infant will lift the leg up to step on to the table. The walking reflex is obtained by holding the infant upright so that the sole of the foot presses against the table. This initiates reciprocal flexion and extension of the legs, simulating walking. These reflexes disappear by 6 weeks.	See table (p48) for neurological features that require action.	

**Referral to paediatrics is recommended
for the following neurological features:**








- ◆ A high pitched cry
- ◆ Persistent failure to suck properly
- ◆ Extreme irritability
- ◆ Abnormal posturing e.g. excessive fisting
- ◆ Generalised hypotonia
- ◆ Generalised persistent hypertonia
- ◆ No/very little spontaneous movement or asymmetrical movements
- ◆ Asymmetry of the Moro reflex

5. Growth monitoring



<http://www.hse.ie/eng/health/child/growthmonitoring/>

Growth Parameter	Details	Actions	Relevant to Contact Points
Weight	A baby's birth weight is an important indicator for their health. The average weight for term babies is approximately 3.2 kg. Newborn babies may often lose 5-7% of their birth weight, and will regain this within 2-3 weeks. The weight should be recorded and plotted on the UKWHO Growth chart if applicable.	Weight should be measured at all contacts. It should be plotted on the appropriate UK-WHO Growth Chart at contact points 1 & 3 (see below for why this measurement is not plotted at contact point 2.) Consider paediatric review if weight loss of > 10%, or if the weight is dropping percentile lines on the growth chart.	
Length	The baby's length should be measured from the top of the head to the heel of one foot. This should be plotted on the appropriate UK-WHO chart (if applicable see box below). For practical purposes, at the bedside this is normally done with a disposable paper tape. It is worth noting that this is not the most accurate way to measure length, and if there are concerns regarding length an alternative technique should be considered.	Length should be measured at all contacts. It should be plotted on the appropriate UK-WHO Growth Chart at contact points 1 & 3. Consider paediatric review if the length is less than the 0.4th centile, or if weight and length are more than two percentile lines apart on the growth chart. Consider paediatric referral if length is over 99.6th centile & other dysmorphic features are present.	
Head circumference or occipito-frontal head circumference (OFC)	It is critical to <ul style="list-style-type: none"> ◆ plot (if applicable) ◆ to act if outside normal range ◆ to use consistent technique (disposal paper "Lasso" tapes at the correct position on the head) ◆ to measure three times and plot the largest of the three measurements 	Head circumference should be measured at all contacts. It should be plotted on the appropriate UK-WHO Growth Chart at contact points 1&3. At or around the time of birth, if the OFC is greater than 38 cm or less than 32 cm obtain cranial ultrasound and refer to paediatrics.	 

Growth Parameter	Details	Actions	Relevant to Contact Points
Head circumference or occipito-frontal head circumference (OFC)	<p>In normal infants the head circumference is related to the size of the infant, particularly the body weight. Record on the UK -WHO Growth Monitoring chart.</p> <p>On the centile chart, the head circumference and the weight should approximate to each other.</p>	<p>At the six week check, referral to a specialist paediatrician or paediatric neurosurgeon is usually recommended if head circumference measurements are below the 0.4th centile or above the 99.6th centile, or if they are dropping or rising through two or more centile spaces.</p>	

At the first full newborn clinical examination and at the 6 week check these measurements should be plotted on the appropriate UK-WHO Growth chart.

In ALL cases inform the parents of the result. Record the result in the notes. Include the result in the discharge letter to the GP and PHN. If the PHR is being used then record the result in the PHR.

Why are there no centile lines between birth and 2 weeks?

Weight gain in the early days varies a lot from baby to baby, so there are no lines on the chart between 0 and 2 weeks. Having a gap emphasises the importance of looking at weight gain relative to birth weight in first days, not centile position.

6. Infant mental health

Infant mental health refers to the behavioural and social development of children from birth to the age of three. Research has shown that babies are born biologically programmed to seek contact and to form relationships. The care giver is the baby's first relationship, and **first relationships matter**. Parents may be surprised to discover that their baby is drawn to their face, their voice and their smell and indeed craves physical contact. Encourage parents to follow their baby's cues and to talk and sing to their baby. These behaviours help them to form a strong attachment or bond with their baby.

The Newborn Clinical Exam can be used as an opportunity to demonstrate this to the parent, encouraging early relationship building strategies such as following the baby's cues, talking, singing to, and holding their baby. These behaviours help them to form a strong attachment or bond with their baby.

7. Health promotion

The newborn clinical examination is a wonderful opportunity for a healthcare professional to engage and involve parents in the health of their newborn baby, and to offer opportunistic health promotion.

Messages that can be delivered at this time include:

- ◆ The importance of breastfeeding
- ◆ Nutrition and weaning
- ◆ SIDS prevention
- ◆ Prevention of accidents and injuries
- ◆ Immunisations
- ◆ Recognition of illness



Key messages for all the contact points

Smoking	<ul style="list-style-type: none"> ✓ Tobacco smoke harms your baby's health and increases their risk of dying from cot death. ✓ Protect your baby by eliminating exposure of your baby to second hand smoke by making your house and car smoke free and don't allow anyone to smoke around your baby.
Breastfeeding, nutrition and weaning	<ul style="list-style-type: none"> ✓ Your breastmilk gives your baby all the nutrients they need for around the first 6 months (26 weeks). ✓ Every breastfeed makes a difference. ✓ The HSE website www.breastfeeding.ie provides lots of useful information and there are experts available online to answer your queries. ✓ If you choose not to breastfeed your baby (or are unable to breastfeed or to express milk) a 'first milk'/standard infant formula should be the sole source of nutrition for up to 6 months (26 weeks).
SIDS prevention	<ul style="list-style-type: none"> ✓ Always place your baby on their back to sleep, even for naps. ✓ Place their feet to the foot of the cot, and with head and face uncovered. ✓ Keep cot free of soft objects and pillows, positioners, bumpers and toys. ✓ The safest place for your baby to sleep is in a cot/Moses basket in your room (for at least the first 6 months).
Prevention of injury	<ul style="list-style-type: none"> ✓ Always use a correctly fitted car seat that is appropriate for your child's weight and length. ✓ Watch your baby at all times, children do not understand danger.
Immunisations	<ul style="list-style-type: none"> ✓ Vaccinate your baby, this will protect them from diseases.
Recognition of illness	<ul style="list-style-type: none"> ✓ Seek medical assistance for your baby if you notice the following: <ul style="list-style-type: none"> ◆ Raised temperature ◆ Poor feeding ◆ Vomiting ◆ Irritability, lethargy ◆ Decreased urine or stools ✓ Trust your instincts. You know your baby better than anyone and if you feel there is something wrong seek medical advice.

8. Summary points

1. Newborn clinical examination takes less than 15 minutes, and should be performed on all babies in a systematic and standardized way at three important contact points:



Within 72 hours of birth



Within 72 hours of discharge from hospital



At 6 weeks

2. This routine physical examination excludes obvious abnormalities and screens for other, less obvious conditions. The examiner needs to understand normal newborn appearance and behaviour in order to detect abnormalities.
3. Most serious congenital anomalies can be detected at birth, or within a few days, provided the examiner is aware of these anomalies and knows the “red flag” signs that may herald their presence. Some of these “red flag” conditions could endanger the life of the newborn. The detection of these red flags greatly increases the chance of successful treatment being commenced.
4. Some significant abnormalities may not be detected in the immediate newborn period, particularly some congenital cardiac diseases. This is often due to the limitations of the newborn clinical examination rather than the technique of the examiner. Parents may become distressed or angry when a significant abnormality is diagnosed at a later stage. Therefore it is important to educate them that not all abnormalities can be detected at the initial examination. It is also important to document all findings, both positive and negative, clearly.
5. Screening for other conditions such as developmental dysplasia of the hip or congenital cataract facilitates early detection and treatment. This may prevent or greatly reduce the risk of permanent residual disability.

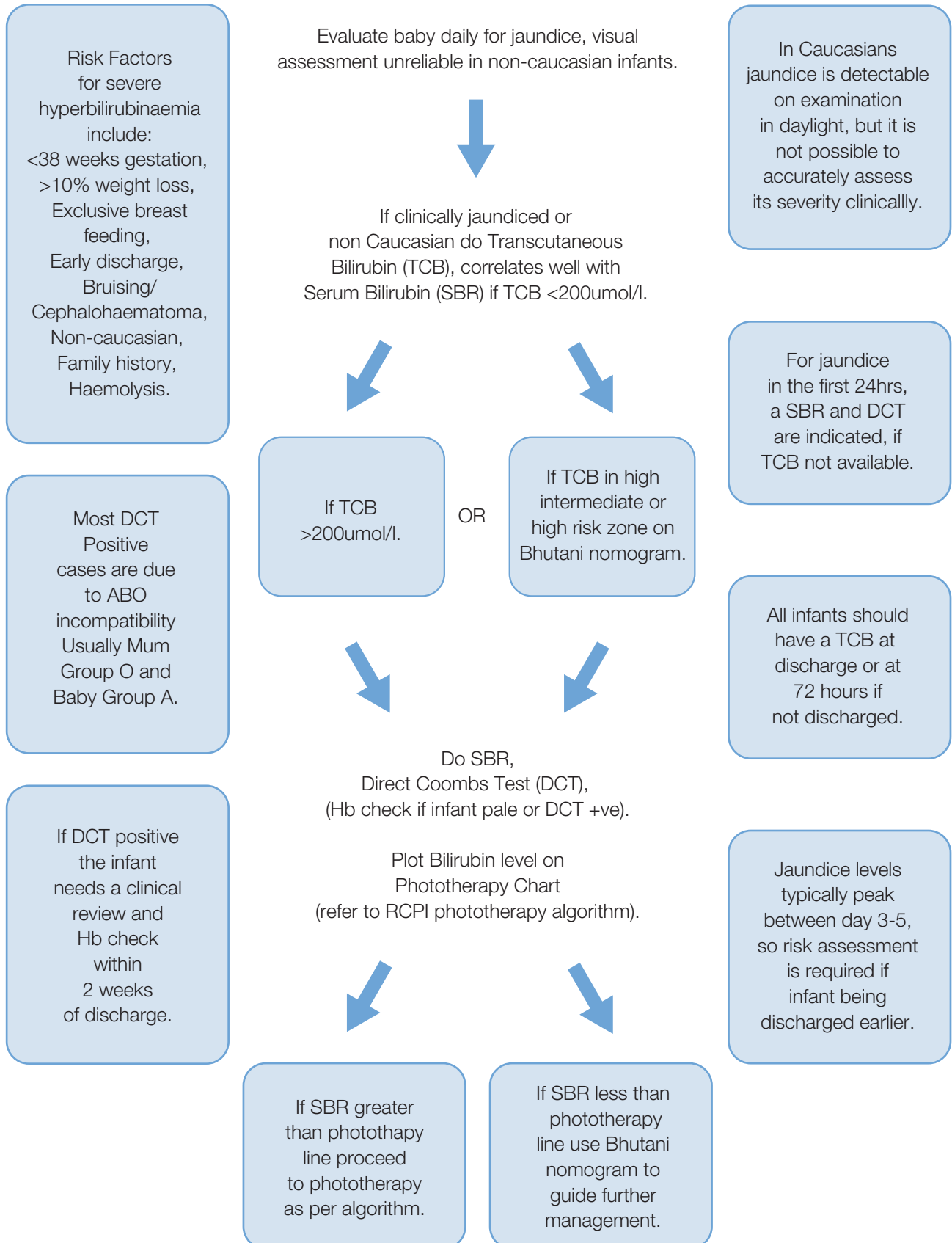
Screening assessments for:	Assessing for red flag issues:
<ul style="list-style-type: none"> ◆ Metabolic conditions - Newborn bloodspot screening – this can be carried out in hospital or by the PHN at the 72hr visit. ◆ Hearing - Neonatal hearing screening – check that it has been completed. ◆ Congenital cataract - Eyes – complete as part of newborn clinical exam. ◆ Congenital heart disease - Heart - complete as part of newborn clinical exam. ◆ DDH - Hips - complete as part of newborn clinical exam. ◆ Undescended testes - Testes - complete as part of newborn clinical exam. 	<ul style="list-style-type: none"> ◆ Jaundice ◆ Cleft palate ◆ Bilateral choanal atresia ◆ Erb's palsy ◆ Congenital cataract ◆ Congenital heart disease ◆ Abnormalities of the genitalia ◆ Anorectal malformations ◆ Postural & structural talipes ◆ Neurological features

Remember, with all examinations, results are vital. It is important that the examiner discusses all of the findings with the parents, that these findings are documented in the child's medical notes and communicated in discharge correspondence to GPs and to PHNs.

Like any new skill, performing a newborn physical examination can initially seem to be a daunting task. It is essential to practice this new skill, always in a standardized way from head to toe. This examination is often very rewarding for the practitioner, it is a wonderful opportunity to engage parents and carers in the health and wellbeing of their newborn baby, and with practice you will hone your communication skills in addition to your examination skills.



Appendix 1 - Term Infant with Neonatal jaundice on postnatal ward



Appendix 2 - Management of a baby with jaundice in the community



1. Check the naked baby in bright, preferably natural light
2. Examine the sclerae and the gums
3. Press lightly on the skin to check for jaundice in blanched skin
4. Check the hospital discharge summary

JAUNDICE PRESENT

Is the baby less than 24 hours old?

YES
→

Refer to the paediatric doctor on call as the baby needs urgent investigation.

NO

For babies aged between 24 hours and 14 days
Perform a clinical assessment

- Have you any clinical concerns?
- Factors to take into consideration:
 - Gestational age < 38 weeks
 - Family history of early or severe jaundice
 - Exclusive breastfeeding
- Does the baby have any of the clinical features outlined in Table 1*?
- Has the parent reported a worsening of jaundice?

YES
→

Refer to the paediatric doctor on call if any clinical concerns.

NO

Is the baby older than 14 days?

- This is prolonged jaundice
- Perform clinical assessment checking for features in Table 1* prior to referral

YES
→

Contact paediatric doctor on call to arrange assessment. This is to rule out causes such as

- Infection
- Galactosaemia
- GI pathologies including biliary atresia

NO

For all infants:

- Educate the parents about the significance of jaundice, but reassure them that it is common
- Advise parents regarding features to look out for and who to contact if they are concerned
- Encourage frequent breastfeeding, and to wake the baby for feeds. Refer for breastfeeding support if necessary
- Consider reviewing the baby again in 24-48 hours. Document your findings

Breast milk jaundice is a common cause of prolonged jaundice but this is a diagnosis of exclusion.

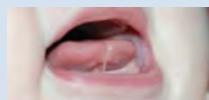*** Table 1 - Clinical Features of concern**

<ul style="list-style-type: none"> • Weight loss of >10% of birth weight • Lethargy • Tachycardia • Unstable temperature • Poor feeding/not waking for feeds 	<ul style="list-style-type: none"> • Persistent vomiting • Poor urine output • Not passing stool/meconium • Apnoea • Irritability/changed behaviour
--	--

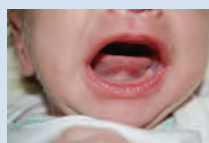Appendix 3 - Management of Tongue-Tie in Early Infancy

TYPES OF TIE

Anterior Tie (Types I and II)



Posterior (submucosal) Tie (Types III and IV)



Frenotomy could be considered in healthy infants with a tongue-tie who present with a problem feeding.

All professionals agree that tongue-tie on its own without feeding problems does not necessarily require frenotomy.

Good lactation/feeding assessment is crucial to support babies with a tongue-tie.

It is uncertain whether anklyoglossia (tongue-tie) is a congenital oral anomaly or whether it is a normal variant.

A small number of mothers may experience breastfeeding difficulties. This has been attributed to apparent tongue tie in the infant, however many mothers experience no difficulty feeding infants with apparent tongue-tie, and infants with apparent tongue-tie generally have no difficulty bottle feeding.

Presenting problems attributed to tongue tie are nipple pain, poor latch, poor feeding, slow weight gain, unsettled infant. However these symptoms are also common in first time breast feeding mothers.

There are many assessment tools (e.g. Hazelbaker), many are very time consuming and of uncertain value. Assessment can be done using the right sidebar:

What to do if tongue tie is suspected:

- Confirm that tongue-tie is present; this should include a full examination of the palate.
- Obtain a lactation consultant assessment prior to any referral for possible tongue tie release procedure. Breastfeeding may be attributable to non tongue tie issues.
- Undertake an oral & systemic examination of the baby to exclude local causes such as cleft palate and systemic causes such as UTI, airway difficulties or cardiac problems.
- If the feeding problem persists, intervention at 2-3 weeks of age may be appropriate before feeding problems make breastfeeding so difficult that the mother stops feeding. If the tongue tie is very obvious and the feeding difficulties are severe intervention may be considered before this.
- Advice should be given on feeding in the interim by Lactation Consultant.
- Ascertain that the baby has been given Vitamin K, and there is no family history of blood dyscrasias.
- Referral by medical practitioner to an appropriately trained professional to assess severity of tongue tie and possible frenotomy.
(‘Tongue Tie Assessment Referral Form’ - available at: <https://www.hse.ie/eng/services/publications/clinical-strategy-and-programmes/paediatrics-tongue-tie-in-early-infancy.pdf>)

Follow the baby and mother up after the frenotomy. If feeding does not improve there is another cause for the difficulties. Some babies who undergo frenotomy continue to have feeding problems despite releasing the tongue tie. Skilled breastfeeding advice and support is essential post procedure.

ASSESSMENT

1. Mother's symptoms:

- Nipple pain; persistent over one week's duration.
- Breast pain, mastitis, engorgement beyond normal initial feeding issues.
- Distorted nipple shape after feed, bleeding or ulcerated nipples.

2. Feeding history:

- Failure or likely failure to regain birth weight by 2-3 weeks of age.

3. Look at Latch:

- Is the infant's latch correct?
- Is latch being maintained?
- Check position of baby at breast.

4. Listen and look:

- Clicking sounds while feeding.
- Pooling milk around mouth during feeds.
- Gasping, struggling on the breast.
- Bobbing around, latch slips

5. Look and palpate:

- Extension (sticking out tongue), elevation (lift of the body of the tongue in the mouth, not just the tip - should reach at least halfway up to the palate) and lateralisation (side to side movement of the tongue - often better to one side with tongue tie).
- Frenulum extends anteriorly to tip of tongue or lower gum line (abnormal).
- No visible frenulum, but tight band palpable under the tongue, query posterior tie.

Appendix 4 - Anorectal malformations

ANORECTAL Malformations

Key points from RCPI guideline:

- ◆ Incidence 1:2500 live births.
- ◆ Misdiagnosis are common with 1 in 5 cases being missed.
- ◆ There are no predisposing factors. It may be associated with polyhydramnios.
- ◆ They are classified into clinical groups depending on the fistula location such as perineal, recto-urethral, recto-vesical; vestibular and those with no fistula and anal stenosis.
- ◆ 71% have additional abnormalities (e.g. VACTERL complex*).
- ◆ Ano-rectal malformations are easy to miss at the routine newborn examination.
- ◆ All babies should have examination of anus prior to discharge.
- ◆ Delayed recognition can lead to complications and distress for parents and the baby.
- ◆ If undiagnosed the infant will develop increasing bowel dilation secondary to the obstruction.
- ◆ Bowel perforation will occur on day 4-5, most commonly in the small intestine.

ANTENATAL:

If ano-rectal malformation is suspected on ultrasound scan antenatally then:

- ◆ If an obstetrician with an interest in Feto-maternal medicine is available then the scans should be discussed with them.
- ◆ Assessment of kidneys and heart should be made.
- ◆ The findings should be discussed with a Paediatric surgeon.
- ◆ The potential for an ARM should be flagged up with the neonatal team and paediatric surgery.
- ◆ Plan for a Paediatrician to be present at the birth.
- ◆ If an ano-rectal malformation is confirmed then active management should be instituted.

On the post-natal ward or at home if home birth/early discharge:

- ◆ Need routine documentation processes for recording passage of a normal stool.
- ◆ Any infant that has not passed meconium by 24-36 hrs should be urgently evaluated by senior staff (55% pass meconium by 12 hrs of age; 76% by 24 hrs (81% at 24hrs in preterm; 71% in babies born by C.S) and 97% by 48 hrs).
- ◆ The infant should have passed a normal meconium stool – Green staining of the napkin is not sufficient as this frequently occurs in cases of anal atresia with a fistula.

*The acronym VACTERL denotes:

- ◆ **V:** vertebral anomalies
- ◆ **A:** anorectal anomalies
- ◆ **C:** cardiac anomalies; cleft lip
- ◆ **TE:** tracheo-oesophageal fistula +/- oesophageal atresia
- ◆ **R:** renal anomalies
- ◆ **L:** limb anomalies

Appendix 5 - Brachial Plexus Injury (Erb's Palsy)

- In rare cases there can be a Horner's syndrome and Phrenic Nerve involvement.
- The Toronto score is widely used by Physiotherapists. It is a grading system of active movement against gravity. A normal score is 10. A score of <3.5 at 3 months indicates poor recovery.
- Narakas is the other scoring system commonly used. It classifies babies into 4 groups - upper Erb's, extended Erb's, total palsy & total palsy with a Horner's.
- If an MRI scan is to be performed it is best to wait for 3 months. If undertaken too soon after the injury the pseudo-meningocele at the point of nerve avulsion may be obscured by oedema.

The risk factors for Brachial Plexus Palsy (BPI) are Shoulder Dystocia and Infant of a Diabetic Mother. If recognised during labour a McRoberts Maneuver is performed. It is effective in releasing the baby's shoulder in 50% of cases.

The infant is noted after birth to have reduced or absent movement of the upper limb. The condition varies widely in both extent and severity. The process is caused by stretching of the brachial plexus nerve fibres.

The mild, common form affects the shoulder muscles C5, C6. The moderate form affects the shoulder, elbow, forearm C5, C6, C7, C8. The severe form affects the shoulder, elbow, forearm, wrist & fingers C5, C6, C7, C8, T1.

In the examination do a Moro reflex & document any asymmetry. Record the presence or absence of shoulder flexion, elbow flexion, supination (with ability to turn the palm upwards), wrist extension and finger movements. Note these findings at each examination. Do an x-ray of the clavicle to exclude an associated clavicular fracture (pseudoparalysis).

Seek physiotherapy involvement at an early stage. The aim in the early stages is graded passive movements of the joints to prevent contractures. No passive shoulder movement for the first 5-7 days.

See back at the clinic at 2 weeks of age. Note the joint movements as previously described. One would expect to see improvement in most cases at this time. Continue to see every 2 weeks over the first 6 weeks. Most cases make quick recovery and only 10% have a residual deficit beyond 3 months of age. Recovery of shoulder flexion & elbow flexion are important prognostic signs. These signs should have recovered by 6 weeks. Both must recover together. If recovery is not present by 6-12 weeks refer to the specialists such as the Erb's Palsy Clinic, CRC, Clontarf or local orthopaedic services.

Good communication with parents is important. It is a condition that causes significant parental anxiety. The concerns are compounded by the initial uncertainty regarding outcome.

- The incidence of Brachial Plexus Palsy is 1.7 per 1000 births. 90% will have recovered or almost recovered by 6 weeks. Ten percent will not recover by 6-12 weeks and will need specialist referral.
- Nerve healing and repair is at a cellular level so careful graded movement is important starting after 5-7 days.
- Early presentation is not often indicative of prognosis.
- Infants often turn away from their affected side so plagiocephaly prevention advice is advised.
- Be aware of the potential for posterior dislocation of humeral head.

Appendix 6 - Infant examination by public health nurse within 72 hours of discharge



Public health nurses are notified of all births and have many interactions with each family. The public health nurse conducts a physical examination of the infant within 72 hours of discharge and is ideally placed to elicit parental concerns. There is a strong educational and supportive focus to this visit in addition to the physical examination.

SYSTEM	FEATURES TO CHECK
Appearance	Colour, posture, activity, breathing behaviour.
Skin	Colour and texture, birthmarks, rashes.
Face	Observe appearance and symmetry.
Nose	Observe for appearance and symmetry.
Eyes	Ask if there were any concerns raised in the hospital.
Mouth	Check palate & tongue.
Ears	Check for placement, shape and symmetry. Enquire as to whether hearing screening was offered.
Head	The head should be examined for size, shape & swellings & the cranial sutures should be palpated.
Neck, clavicles	Check for masses in the neck.
Heart	Check colour of mucus membranes. Ask if there were any concerns raised in the hospital.
Lungs	Observe respirations.
Abdomen	Check umbilical cord. Note any abnormalities.
Genitalia	Ask if there were any concerns raised about male infant's testes in the hospital. Inspect female genitalia.
Spine	Check for sacral dimple. Check skin integrity.
Upper limbs	Check for length, proportion and symmetry, check for extra digits.
Lower limbs	Check for length, proportion and symmetry, check for extra digits. Check if newborn bloodspot screening has been carried out and if not complete the screen.
Hips	Ask if there were any concerns raised in the hospital.
Central nervous system	Check tone, behaviour, movements, posture and reflexes.
Cry	Note the sound of baby's cry.
Infant mental health	Note parental response to the baby and to soothing when crying. Note any parental learning difficulties.
Growth	Record head circumference, weight and length. Ask if growth was plotted in hospital.

HEALTH PROMOTION:

This contact is an opportunity to give the parents advice on the following:

- Breastfeeding
- Nutrition and weaning
- Immunisations
- SIDs prevention
- Prevention of accidents and injuries
- Recognition of illness

SCREENING POINT ACTIONS

NEWBORN BLOODSPOT SCREENING

This test should be offered to all babies.

HEARING

Ensure that newborn hearing screening has been performed.

Advise parents about baby's hearing, see www.hse.ie/newbornhearingscreening

EYES HEART TESTES HIPS

Ask if there were any concerns raised in the hospital at the first newborn physical examination.



This examination is a “screening test” – an opportunity to pick up abnormalities that may have developed since newborn screening. As with any screening test, there will be false negatives and positives.

SYSTEM	FEATURES TO CHECK
Appearance	Colour, posture, activity, breathing behaviour.
Skin	Colour and texture, birthmarks, rashes.
Face	Observe appearance and symmetry.
Nose	Observe size, shape and note if nasal flaring present.
Eyes	Check red reflex, look for opacities. Check for fixing and following.
Mouth	Check palate. Observe size, shape and placement.
Ears	Ensure newborn hearing screening done.
Cranium	Fontanelles.
Neck, clavicles	Check for masses in the neck.
Heart	Check position, rate, rhythm, sounds, murmurs, femoral pulse.
Lungs	Check rate, effort (recession) sounds.
Abdomen	Check shape, palpate to check for hernias and organomegaly.
Anus	Check completeness and patency.
Genitalia	Check for undescended testes in males.
Spine	Check for sacral dimple. Check skin integrity.
Upper and Lower limbs	Check skin integrity, note the proportions, symmetry. Check for extra digits. Check for shape and symmetry, check for extra digits.
Hips	Barlow and Ortolani’s manoeuvres.
Central nervous system	Tone, behaviour, movements, posture. Elicit reflexes.
Cry	Note the sound of baby’s cry.
Growth	Record weight, length and head circumference and plot.
Development	Ask parents if baby has started smiling, if baby is responding to loud noises.
Infant mental health	Note parental response to the baby and to soothing when crying. Screen for maternal post natal depression.

HEALTH PROMOTION:

The six week check is an opportunity to give the parents advice on the following:

- Breastfeeding
- Nutrition and weaning
- Immunisations
- SIDs prevention
- Prevention of accidents and injuries
- Recognition of illness

SCREENING POINT ACTIONS

HEART

Murmurs, thrills, heart sounds, cyanosis, absent or asymmetrical pulses, respirator rate and capillary refill.

If the baby is symptomatic refer urgently to Paeds on Call. Otherwise discuss the findings with a Consultant Paediatrician.

EYES

Check red reflexes and check for fixing and following.

If abnormal refer to Paediatric Ophthalmology.

TESTES

Check both testes have descended. If not in scrotal sac check inguinal canal.

If bilateral undescended testes refer to a senior paediatrician. If unilateral undescended testis, review at 4-5 months. If still undescended refer to a surgeon.

HIPS

Check Ortolani and Barlow tests.

If positive Ortolani or Barlow test, refer for Ultrasound scan.

Appendix 8 - Recommendations 6.1 from DDH Subgroup

6.1 Recommendation 1

Babies that have a positive clinical examination at birth should have:

- ◆ A consultation with an expert (paediatrician or orthopaedic consultant) within two weeks.
- ◆ An ultrasound and harness as soon as possible after identification but **no later than two weeks** of age. Ideally the ultrasound should be done within 3 days with immediate harnessing if DDH (i.e. dislocated and dislocatable hips) is confirmed.
- ◆ If available, a multidisciplinary hip clinic with Physiotherapy, Radiology and Paediatric input is preferred. This would need to be held at least once a week.
- ◆ Immediate treatment (if required) as advised, usually by putting them in a Pavlic Harness.
- ◆ Babies with a negative ultrasound at or before 2 weeks should have a further ultrasound at 6 weeks.
- ◆ Further management under the care of the orthopaedic services.

List of Subgroup Members

Nominee	Title	Organisation
Ms Carmel Brennan	Programme Manager CPH	Health and Wellbeing, HSE Midlands
Ms Geraldine Duffy	Assistant Director of Midwifery and Nursing	National Maternity Hospital, Holles St
Dr Davina Healy	Principal Medical Officer	HSE Dublin
Ms Paula Kelly	Consultant Paediatric Orthopaedic Surgeon	Chair of Irish Paediatric and Orthopaedic Society
Dr. Eoghan Laffan	Consultant Radiologist	Children's University Hospital, Temple Street and National Maternity Hospital, Holles St
Dr Ruth McDermott	SpR, Public Health Medicine	Public Health, HSE
Dr Caroline Mason Mohan (Chair)	Consultant in Public Health Medicine	Public Health, HSE NW
Ms Michelle Megan	Director of Public Health Nursing	National Director of Public Health Nursing Group
Mr. David Moore	Consultant Paediatric Orthopaedic Surgeon	Our Lady's Children's Hospital, Crumlin
Prof. John Murphy	Consultant Neonatologist	National Maternity Hospital, Holles St
Dr. Ethna Phelan	Consultant Radiologist	Our Lady's Children's Hospital, Crumlin
Ms Margaret Rafferty	Physiotherapy Manager for Paediatric and Neonatology	AHP Rep to National Clinical Programme
Dr. Ailbhe Tarrant	Consultant Radiologist	The Rotunda Hospital
Ms Grace Turner	Paediatric Clinical Programme Project Manager	Royal College of Physicians of Ireland

Appendix 9 - Professional Bodies consulted with

Number invited to participate in the consultation process:

- ◆ ICGP
- ◆ Head of RSCI Paediatrics
- ◆ HSE Paediatric & Neonatal Clinical Advisory Group
- ◆ HSE Working Group for Integrated Care Programme for Children
- ◆ HSE National Clinical Programme for Obstetrics & Gynaecology
- ◆ HSE Women & Infants Health Programme Office
- ◆ HSE Directors of Midwifery
- ◆ HSE Directors of Public Health Nursing
- ◆ School of Nursing & Midwifery Trinity
- ◆ School of Nursing & Midwifery NUIG
- ◆ School of Nursing & Midwifery UCC
- ◆ School of Nursing & Midwifery UL
- ◆ School of Nursing, Midwifery & Health Studies UCD
- ◆ School of Nursing, Midwifery & Health Studies Dundalk IT
- ◆ Professor of Paediatrics & Adolescent Medicine UCD
- ◆ Professor & Head of Paediatrics Trinity
- ◆ Professor & Head of Paediatrics UCC
- ◆ Professor & Head of Paediatrics NUIG
- ◆ Professor of Paediatrics UL
- ◆ Education specialists RCPI
- ◆ National Child Health Steering Group
- ◆ Principal Medical Officers in the HSE

Number of professionals who provided feedback:

- ◆ ICGP
- ◆ Professor & Head of Paediatrics Trinity
- ◆ Professor of Paediatrics UL
- ◆ Education specialists RCPI
- ◆ HSE Paediatric & Neonatal Clinical Advisory Group
- ◆ HSE Women & Infants Health Programme Office
- ◆ HSE Directors of Midwifery
- ◆ HSE Directors of Public Health Nursing
- ◆ School of Nursing & Midwifery Trinity
- ◆ School of Nursing & Midwifery NUIG
- ◆ School of Nursing & Midwifery UCC
- ◆ School of Nursing & Midwifery UL
- ◆ School of Nursing, Midwifery & Health Studies UCD
- ◆ School of Nursing, Midwifery & Health Studies Dundalk IT
- ◆ National Child Health Steering Group
- ◆ Principal Medical Officers in the HSE

Glossary

Ambiguous genitalia	Rare condition where the baby's external genitalia are not obviously male or female.
Anal atresia	Imperforate anus. The anus is covered by tissue that ranges in thickness from a thin membrane to tissue that is several cm thick. A fistula often extends from the anal pouch to the vagina, the fourchette or the bladder in females, and the perineum or the urethra in males.
Breech presentation	Describes the position of the baby in utero, whereby he/she is lying with bottom or feet pointing downwards.
Central cyanosis	Blue appearance of the mucous membranes and/or skin that is a sign of low levels of oxygen in the blood.
Cephalic presentation	Describes the position of the baby in utero, whereby he/she is lying with head pointing downwards.
Choanal atresia	Rare condition where the baby is born with a blockage or narrowing at the back of the nasal passages.
Clinodactyly	Abnormally bent or curved finger. May present as part of an associated syndrome such as Down's Syndrome.
Coarctation of the aorta	Congenital heart defect that causes a narrowing of the aorta.
Congenital anomalies	Structural or functional anomalies that occur in utero and may be identified during the newborn clinical examination.
Congenital adrenal hyperplasia	Group of genetic disorders where the adrenal gland is larger than normal (hyperplasia). Each of these disorders involves deficiencies in the enzymes involved in the production of aldosterone and/or cortisol. Associated with ambiguous genitalia.
Congenital cataract	Lens opacity present at birth that can cause severe visual impairment if not recognised early.
Congenital glaucoma	Rare condition caused by a developmental abnormality affecting the trabecular meshwork ("drainage system") of the eye, resulting in increased intraocular pressure.
Cutis marmorata telangiectatica congenital	Birthmark that affects the blood vessels of the skin causing a "net-like" pattern on the skin.
Developmental dysplasia of the hip (DDH)	Condition whereby the hip joint has not formed normally. The hip joint is "loose" and in some cases can be dislocated. If not identified and treated early, this can cause problems with walking and also in later life.
DiGeorge syndrome	Also known as velocardiofacial syndrome and 22q11 deletion. This can cause a range of structural defects including facial anomalies, congenital malformations of the great vessels, thymic hypoplasia and absent parathyroid glands.

Erb's palsy	Nerve palsy rarely caused by obstetric brachial plexus injury that can cause weakness in the baby's shoulder, arm or hand.
Erythema toxicum	Harmless rash affecting 50% of newborns that has a "nettle sting" appearance.
Fistula	Abnormal passageway that connects two organs or vessels that do not normally connect.
Haemangioma	Collection of blood vessels that form a red lump under the skin.
Jaundice	Common condition of newborn babies that causes yellowing of the skin and the sclera.
Klippel-Feil syndrome	This is a bone disorder present from birth in which there is abnormal fusion of two or more cervical vertebrae.
Maternal chorioamnionitis	Infection, usually bacterial, of the foetal membranes (amnion and chorion).
Micrognathia	Term given for the small jaw that is often associated with Pierre Robin Sequence (see below)
Mongolian blue spot	Type of birthmark that is usually blue or grey in colour and commonly is found at the base of the spine.
Noonan syndrome	Genetic disorder which can cause characteristic facial features, webbing of the neck, short stature and congenital cardiac anomalies. It may cause intellectual disability and affects both genders.
Oesophageal atresia	Congenital condition in which the oesophagus does not develop properly.
Pierre Robin Syndrome	Sequence Condition present from birth that causes babies to have a small jaw (micrognathia), cleft palate and large tongue. It can cause problems with breathing and feeding in the early newborn period.
Port wine stains	Flat red or purple mark that is noticed on the skin at birth.
Ptosis	Drooping of the upper eyelid that can prevent normal visual development.
Recto-vaginal fistula	Abnormal connection between the rectum and the vagina that may be associated with anal atresia.
Recto-vesical fistula	Abnormal connection between the rectum and the bladder that may be associated with anal atresia.
Retinoblastoma	Rare form of cancer that develops in the retina and is usually found in young children.
Right ventricular hypertrophy	Enlargement of the right ventricle of the heart.

Shoulder dystocia	Vaginal cephalic delivery which requires additional obstetric manoeuvres to be used when the shoulders fail to rotate and descend in the maternal pelvis after the delivery of the head and standard downward traction by the midwife/obstetrician.
Syndactyly	Joining or “webbing” of digits
Subconjunctival haemorrhage	Bleeding underneath the conjunctiva.
Torticollis	Twisting of the neck whereby the baby has a limited range of movement of the neck, and the baby’s head is tilting to one side while the chin tilts to the other. A small pea-sized lump is sometimes found on the sternocleidomastoid muscle.
Treacher-Collins syndrome	Congenital condition affecting the bones and tissues in the face. It can be associated with an underdeveloped jaw which can lead to breathing and feeding difficulties.
Trisomy 21	Also known as Down’s syndrome. This is a genetic disorder that is one of the most common causes of intellectual disability. It is associated with characteristic physical characteristics and growth delays.
Turner syndrome	Genetic disorder that only affects female babies who are born with only one X chromosome rather than the normal two (XX). Turner syndrome is associated with characteristic features including short stature, webbing of the neck, oedema of the hands and feet and occasionally congenital cardiac anomalies such as coarctation of the aorta.

Bibliography

CSO.ie (2018) Irish Life Tables No. 16 2010-2012 – CSO – Central Statistics Office. [online] Available at: <http://www.cso.ie/en/releasesandpublications/er/ilt/irishlifetablesno162010-2012/>

De-Wagh Granelli, A., Wennergren, M., Sandberg, K. et al. (2009). Impact of pulse oximetry screening on the detection of duct dependant congenital heart disease: a Swedish prospective screening study in 39,821 newborns. *BMJ*, 228(January 08 2), pp. a3037

Green K, Oddie S. The value of the postnatal examination in improving child health *Arch Dis Child Fetal Neonatal Ed.* 2008 Sep;93(5):F389-93

HSE (2013) National Consent Policy Available at: <https://www.hse.ie/eng/about/who/qjd/other-quality-improvement-programmes/consent/>

HSE Growth Monitoring Resources Available at: <https://www.hse.ie/eng/health/child/growthmonitoring/>

HSE Evidence Review for the Child Health Model (Version 3) Health & Wellbeing Division 2016

Royal College of Physicians in Ireland The Impact of Early Childhood on Future of Health Position Paper of the Faculty of Public Health Medicine 2017

HSE An introduction to Children First Available at: <https://www.hse.ie/eng/services/list/2/primarycare/childrenfirst/training.html>

Kemper AR, Mahle WT, Martin GR, et al. Strategies for implementing screening for critical congenital heart disease. *Pediatrics* 2011; 128:e1259.

National Institute for Health and Care Excellence (2016) Jaundice in newborn babies under 28 days CG98 National Institute for Health and Clinical Excellence London

National Institute for Health and Clinical Excellence (2006) Postnatal care up to 8 weeks after birth NICE guideline (CG37)

Paediatric and Child Health Division of the Royal Australasian College of Physicians (2009). Examination of the Newborn Royal Australian College of Physicians Available at: http://www.adhb.govt.nz/newborn/Guidelines/Admission/ExaminationoftheNewborn-08_05_2009.pdf

NIPE Newborn and Infant Physical Examination Service Specification No. 21 Public Health England (September 2018) Available at: <https://www.england.nhs.uk/wp-content/uploads/2017/04/Gateway-ref-07842-180913-Service-specification-No.-21-NHS-Newborn-and-Infant-Physical-Examination.pdf>

NIPE Newborn and Infant Physical Examination Screening Programme Handbook Public Health England (April 2018) Available at: <https://www.gov.uk/government/publications/newborn-and-infant-physical-examination-programme-handbook/newborn-and-infant-physical-examination-screening-programme-handbook>

NIPE Newborn and Infant Physical Examination Screening Programme Standards 2016/2017 Public Health England (April 2016) Available at: https://assets.publishing.service.gov.uk/government/uploads/system/uploads/attachment_data/file/692020/NIPE_Programme_Standards_2016_to_2017.pdf

Queensland Clinical Guideline Routine newborn assessment (previously examination of the newborn baby) MN14.4.V4.R19 Queensland Clinical Guidelines Steering Committee (Oct 2014) Available at: https://www.health.qld.gov.au/_data/assets/pdf_file/0029/141689/g-newexam.pdf

Rahi JS, Dezateux C. National cross sectional study of detection of congenital and infantile cataract in the United Kingdom: role of childhood screening and surveillance The British Congenital Cataract Interest Group. *BMJ*. 1999;318(7180):362-5

Russell, H., McDougall, V., Dutton, G. Congenital cataract. *BMJ* 2011 342:d3075

Shorter D, Hong T, Osborn DA. Screening programmes for developmental dysplasia of the hip in newborn infants. *Cochrane Database of Systematic Reviews* 2011, Issue 9. Art. No.: CD004595. DOI: 10.1002/14651858.CD004595.pub2.

WHO Multicentre Growth Reference Study Group. (2006) WHO Child Growth Standards: Length/Height-for-age, Weight-for-age, Weight-for-length, Weight-for-height and Body Mass Index-for age Methods and Development ISBN 92 4 154693 X.

Acknowledgement List for those involved in the development of the Newborn Clinical Examination Handbook:

- ◆ Prof John Murphy, Consultant Neonatologist, Clinical Lead Paediatric & Neonatology Clinical Programme.
- ◆ Dr. Caroline Mason Mohan, Specialist in Public Health Medicine, Department Of Public Health, Donegal.
- ◆ Ms. Geraldine Duffy, Assistant Director of Midwifery, National Maternity Hospital, Holles Street, Dublin.
- ◆ Ms. Grace Turner, Programme Manager,
Integrated Care Programme for Children, Clinical Strategy & Programmes Division.
- ◆ Ms. Carmel Brennan, Programme Manager,
National Healthy Childhood Programme, Dept Public Health, Tullamore.
- ◆ Dr. Fiona McGuire, Senior Medical Officer Public Health,
Dept Public Health, Tullamore (joined the group in October 2016).
- ◆ Dr. Jacqueline McBrien, Consultant Paediatrician, HSE Midland Regional Hospital Portlaoise,
(Community Paediatrician with special interest in Child Health) (Resigned from the group in April 2017).
- ◆ Dr. Jana Semberova, Consultant Paediatrician, Coombe Women and Infant's University Hospital,
Midlands Regional Hospital Portlaoise/ Our Lady's Children's Hospital Crumlin (joined the group in May 2017).
- ◆ Ms. Jacinta Egan, Administrative Support,
National Healthy Childhood Programme, Dept Public Health, Tullamore.

With special thanks to:

- ◆ Prof Alf Nicholson, Consultant Paediatrician,
National Clinical Lead for Paediatrics for National Clinical Programme.
- ◆ Ms Laura Smith, Senior Executive Officer, Dept Public Health, Tullamore.



THE NURTURE PROGRAMME
Infant Health and Wellbeing

ISBN 978-1-78602-113-7